

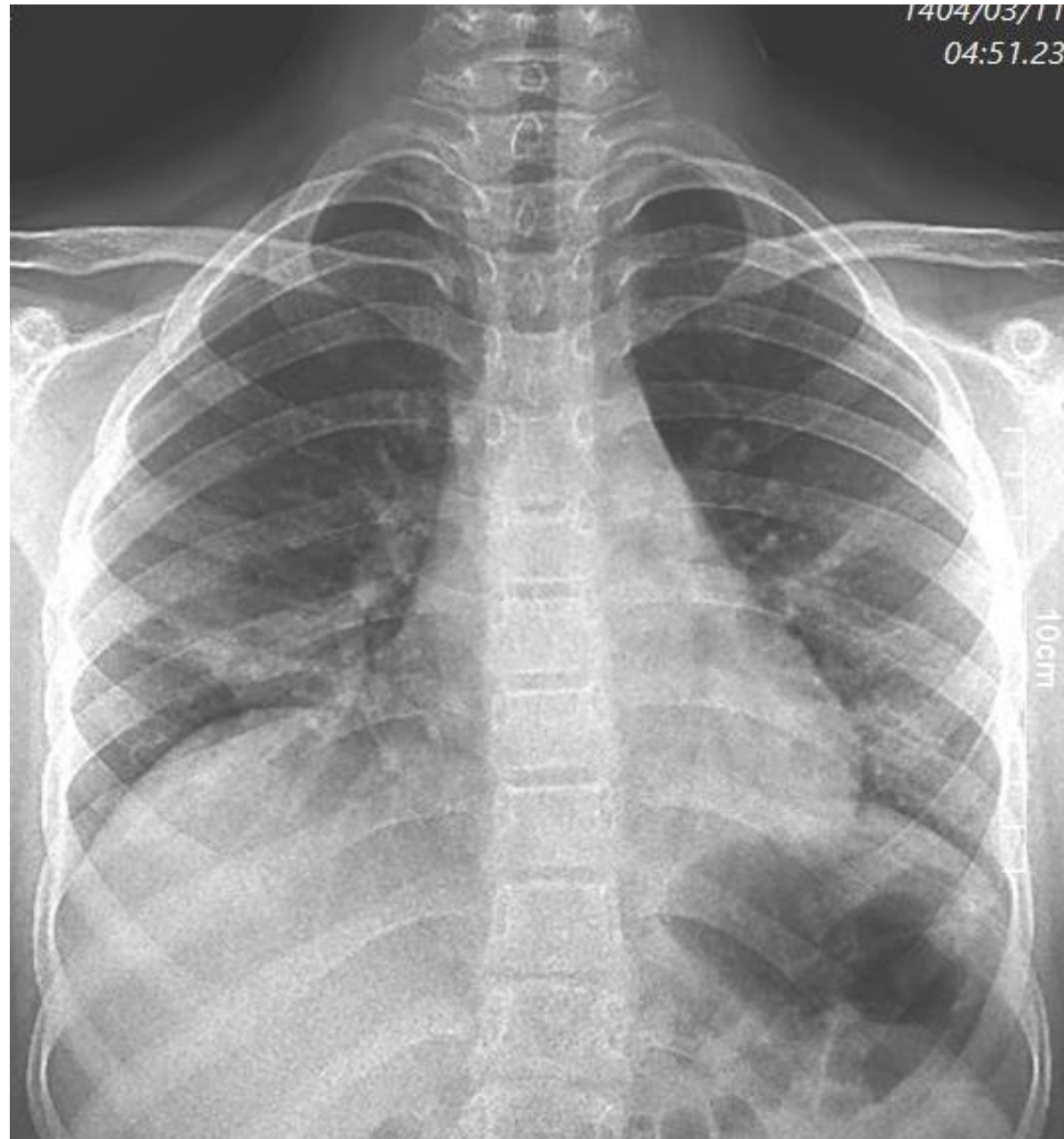Pediatric chest imaging
Interactive
Cased based presentation

M.Alehossein

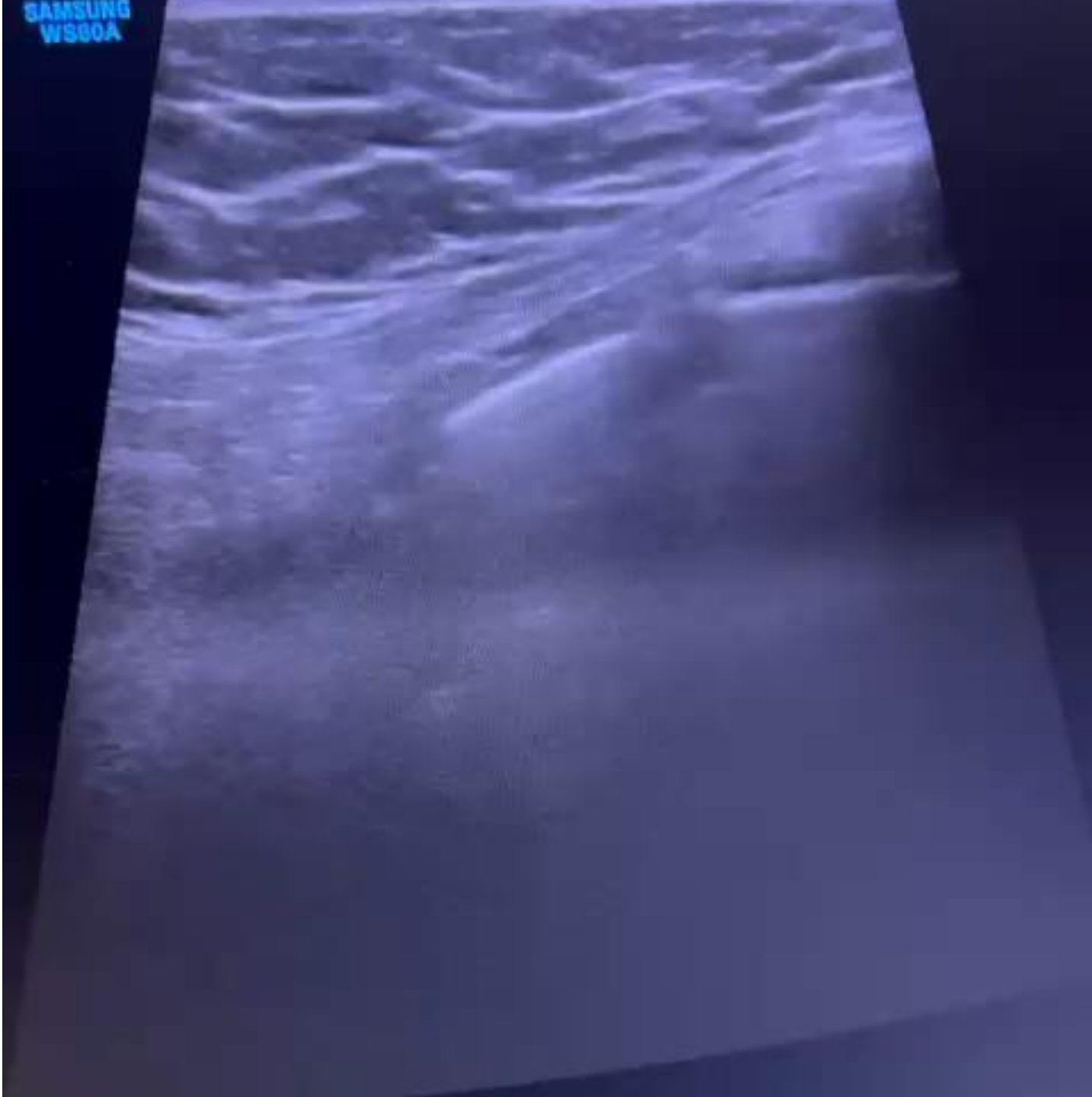Bahrami Children Hospital

TUMS

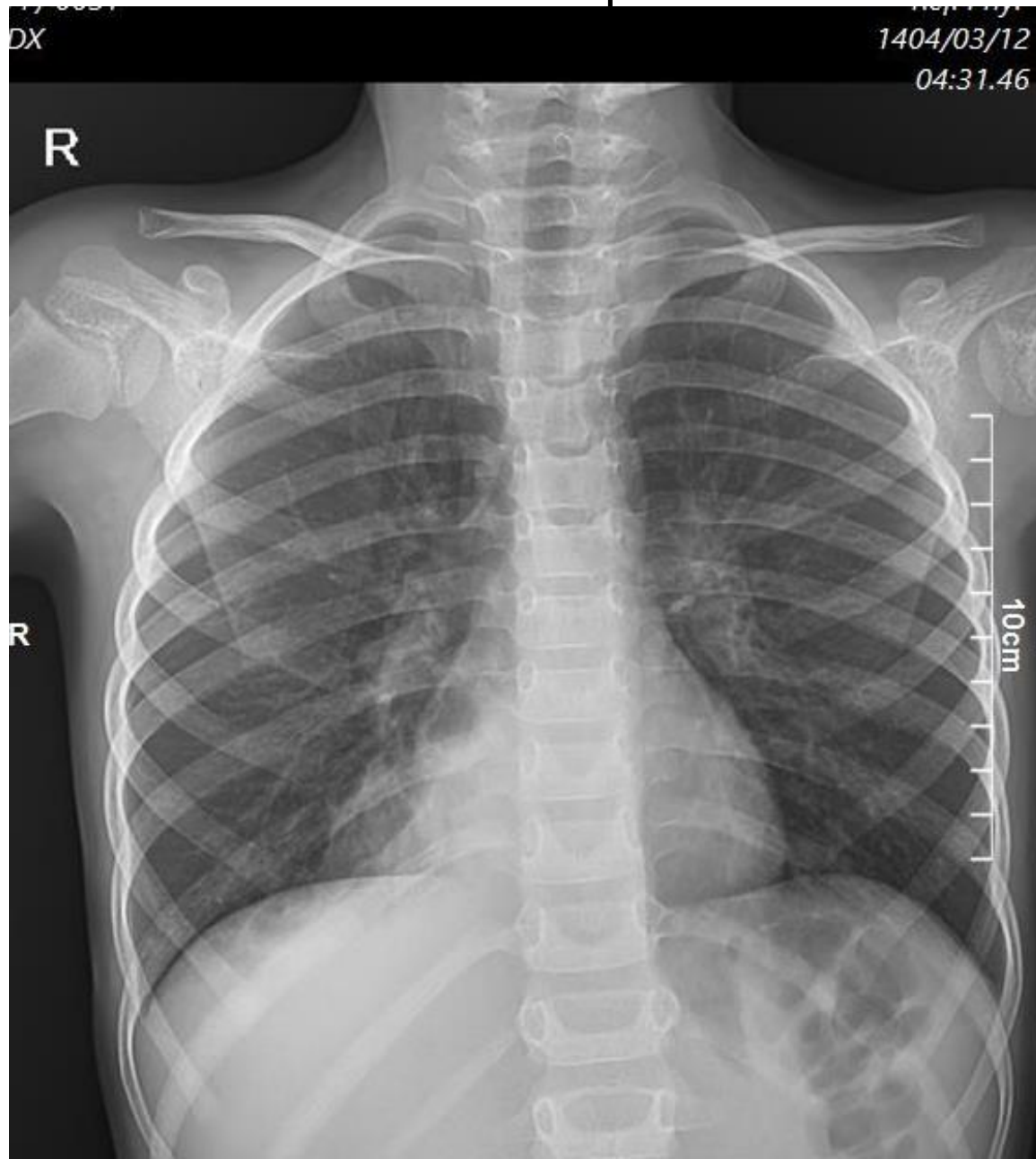
Over diagnosis as pneumonia



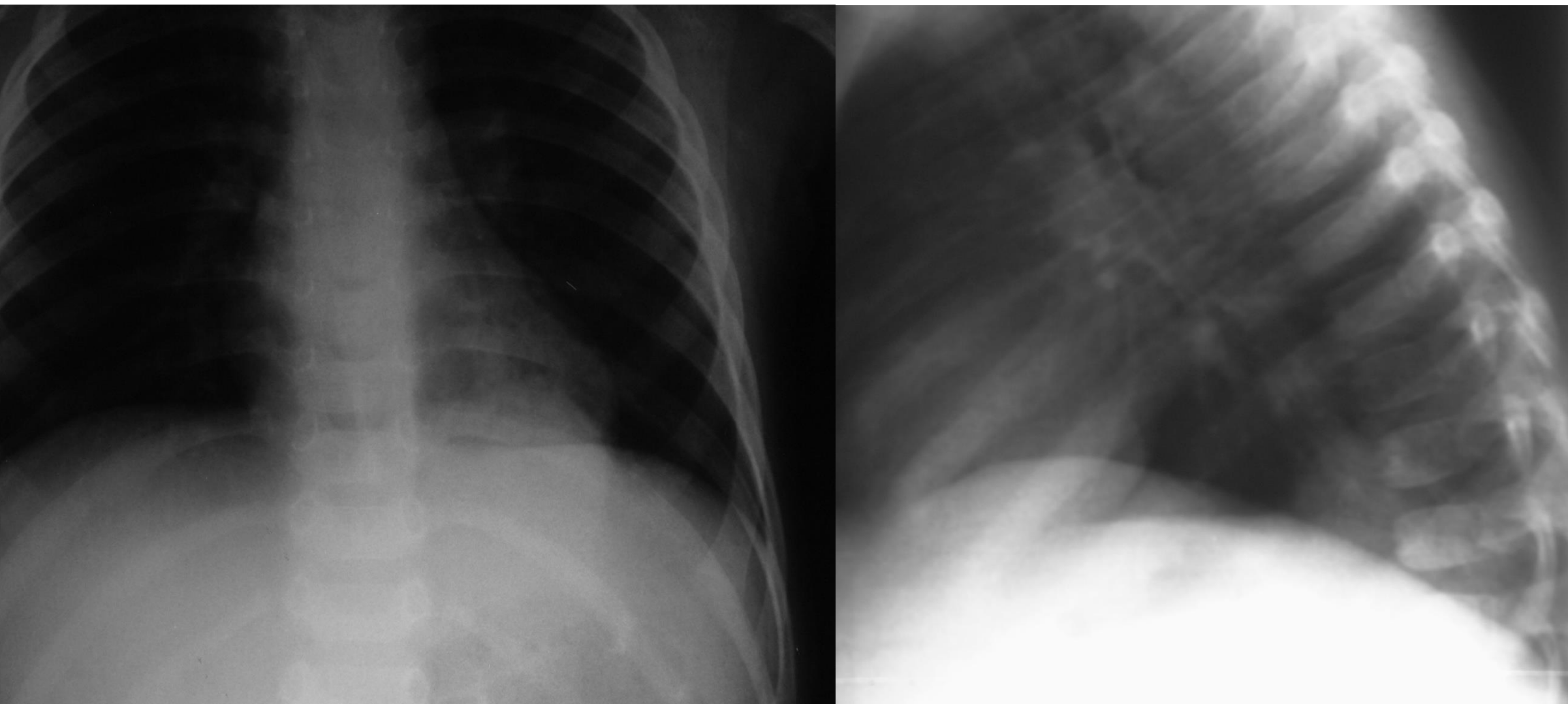
SAMSUNG
WS80A

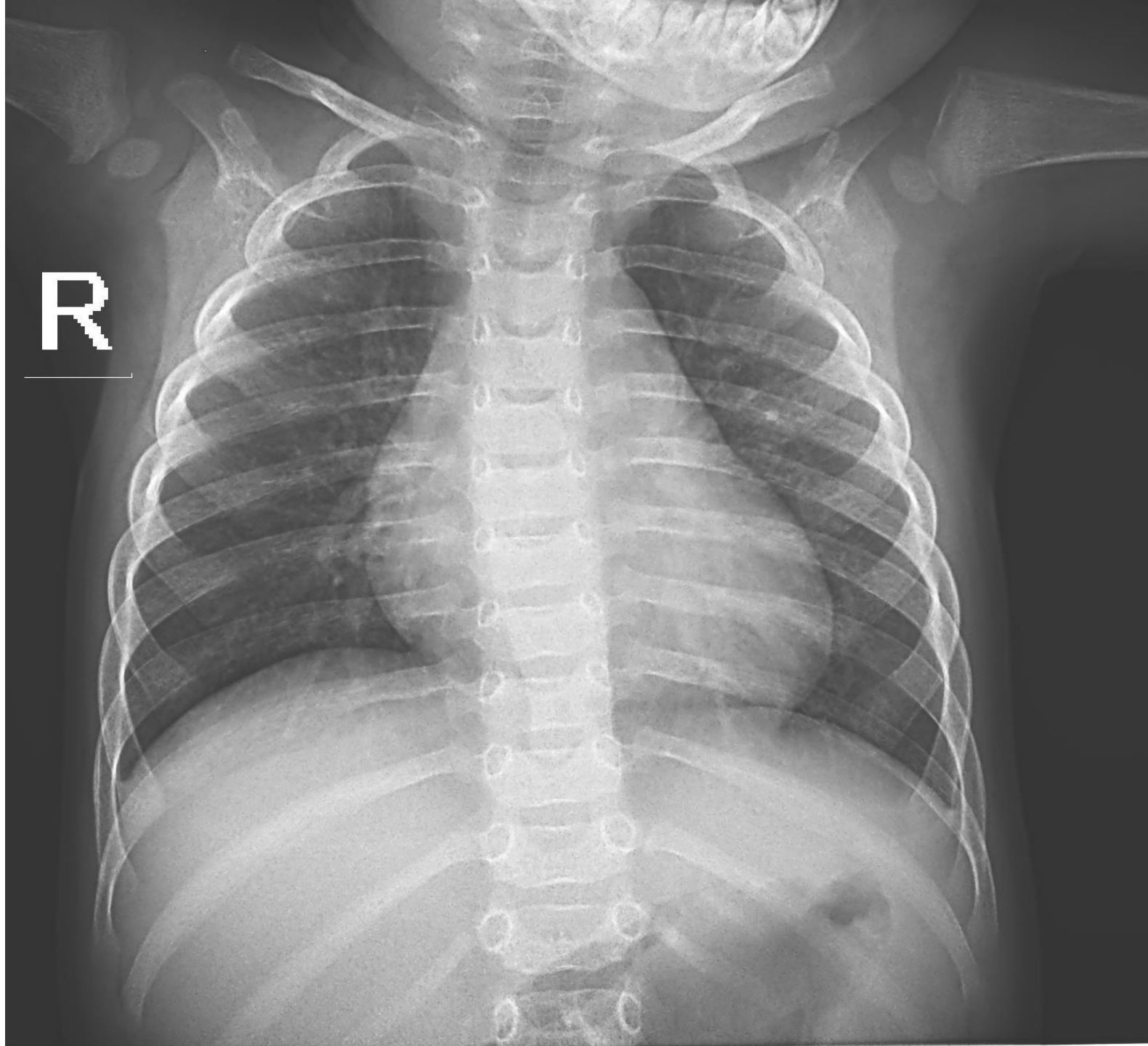


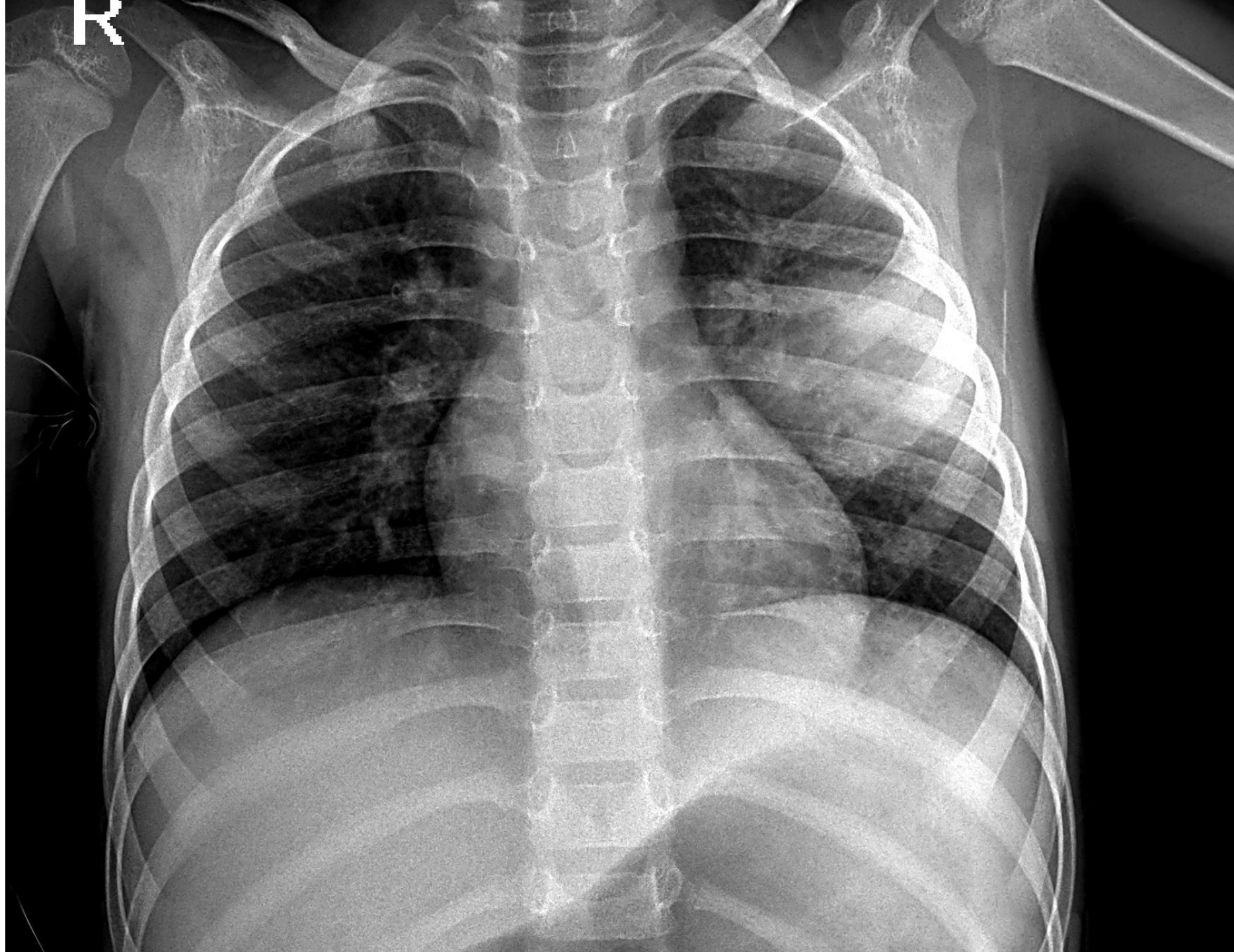Underestimate pneumonia

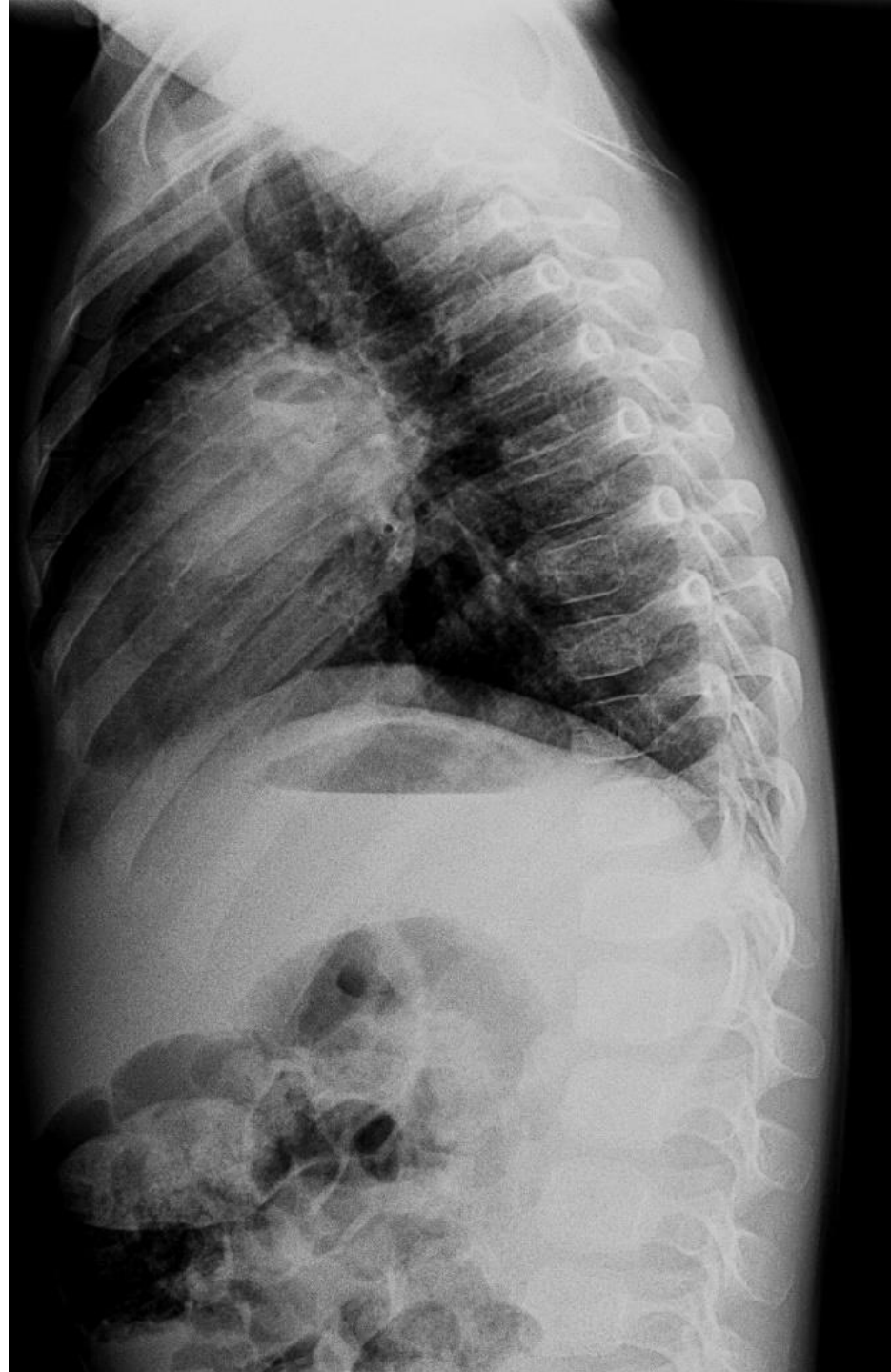


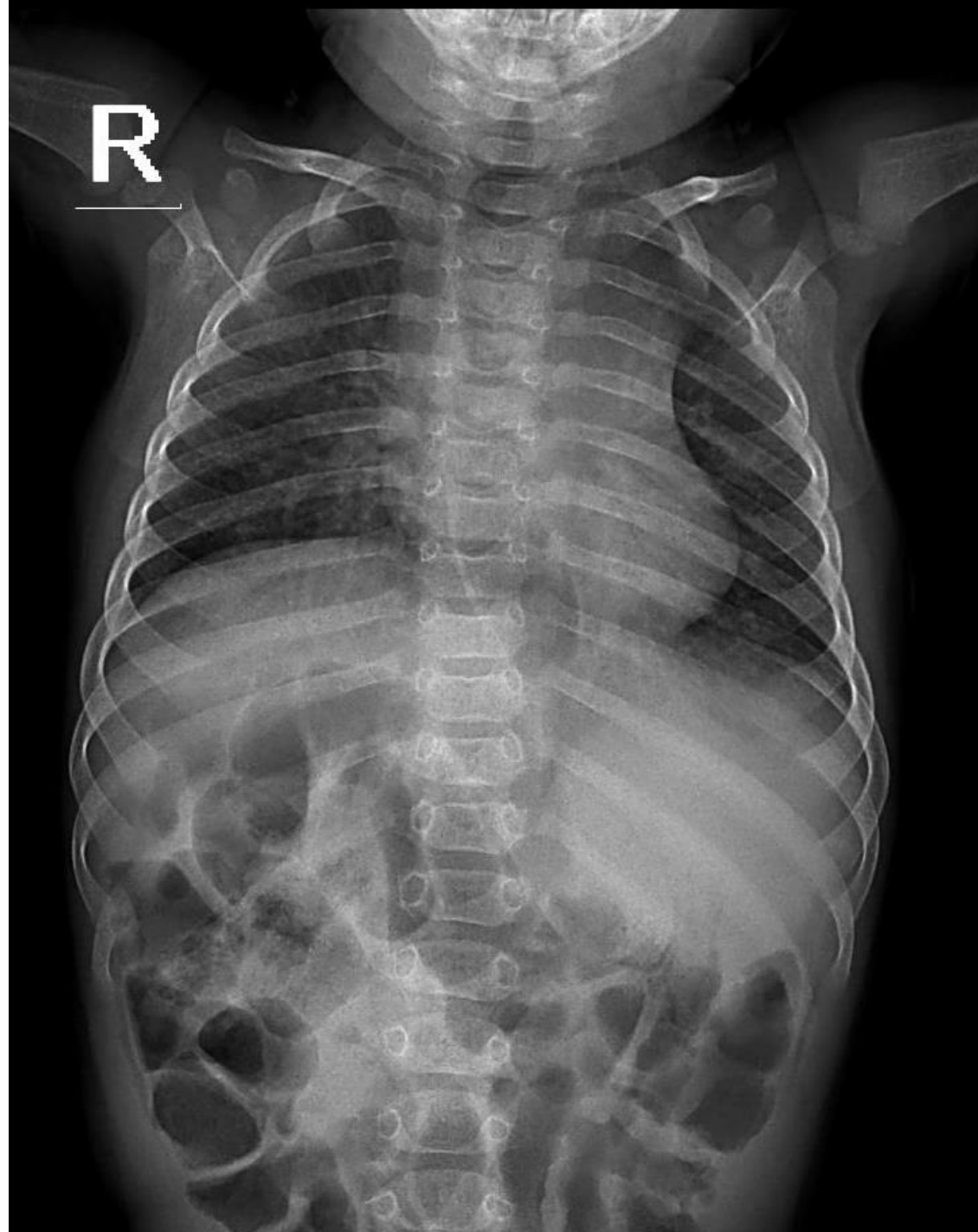Hidden pneumonia



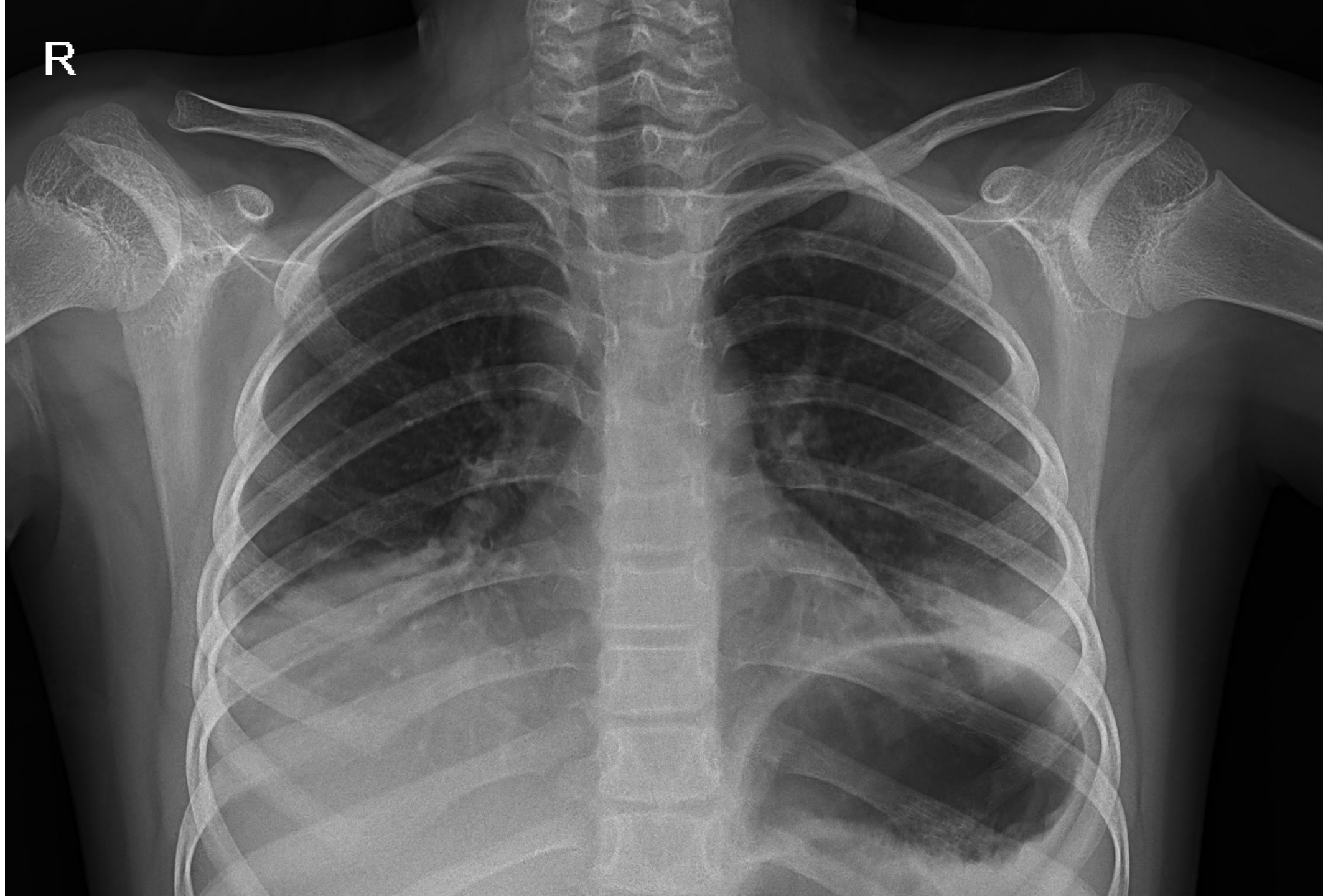


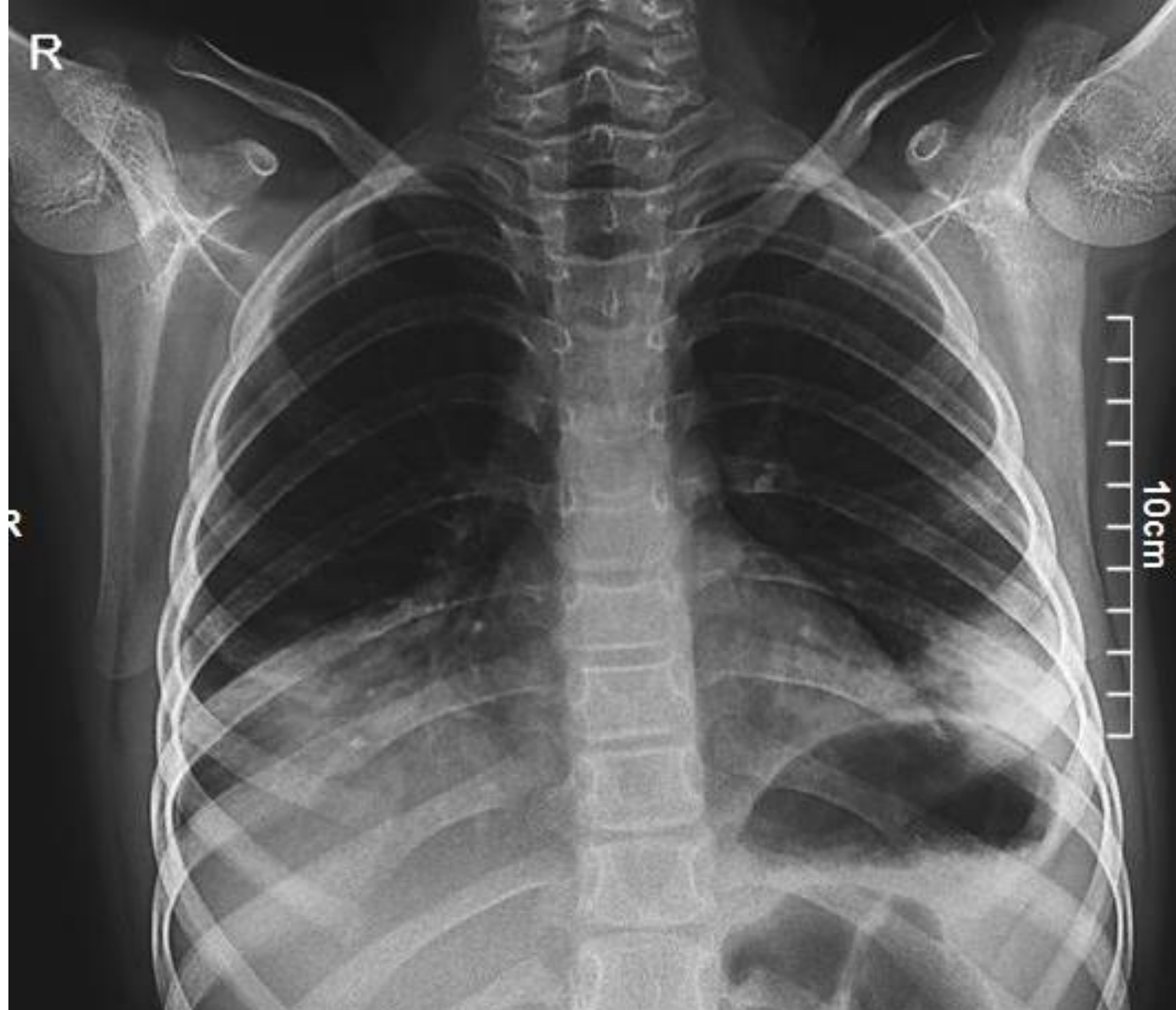


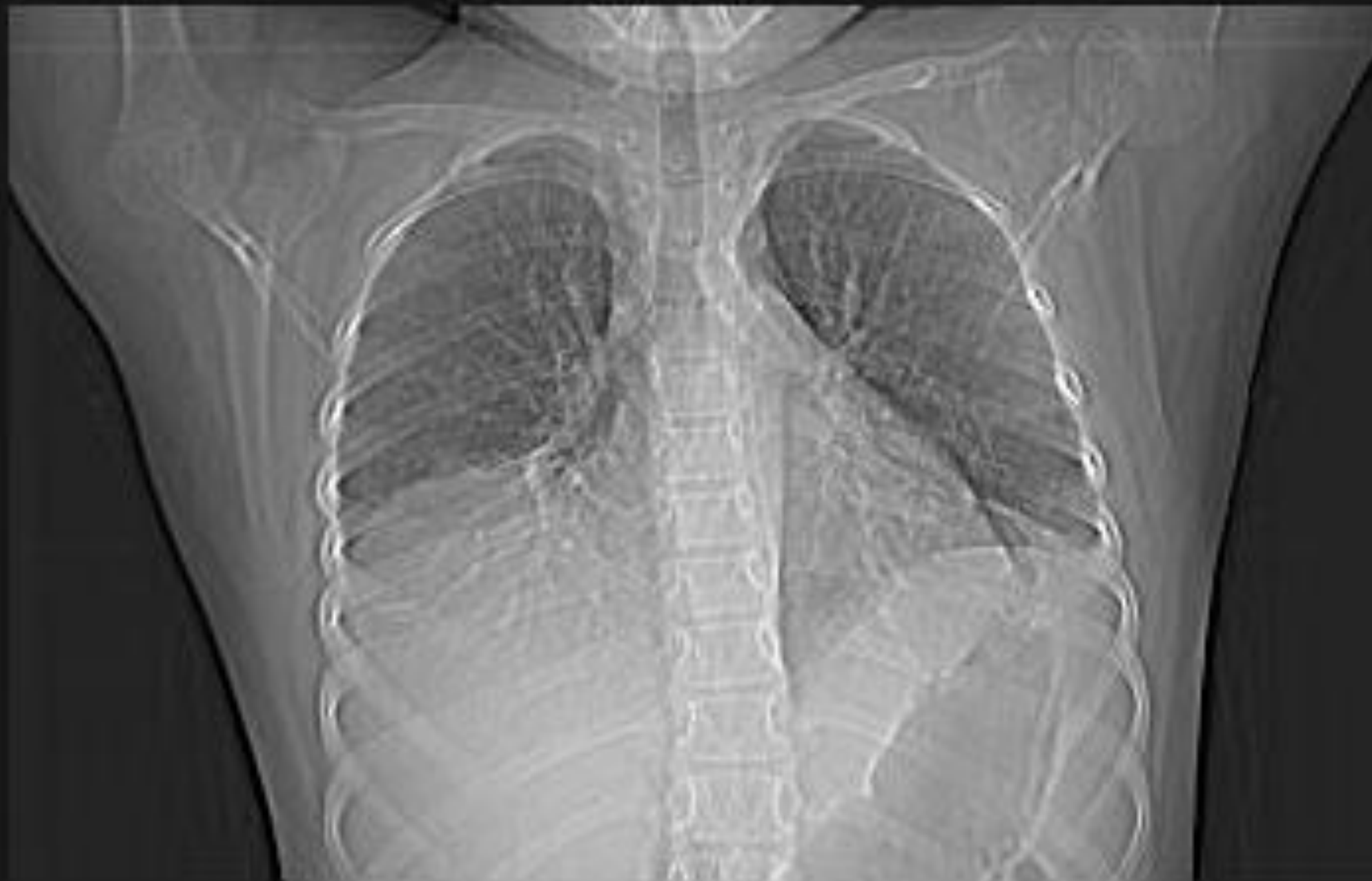

R



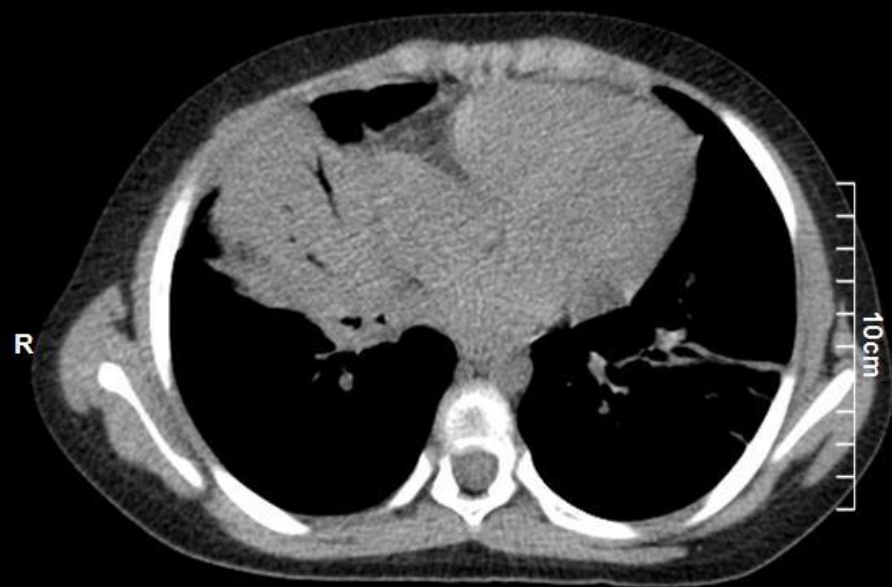




Name: MOSAYEBI^NOORA
ID: 1036863
O / 007Y
CT

A

BAHRAMI HOSPITAL
Operator: N
Ref. Phy:
1403/08/14
12:18.32



im: 40
se: 3
SL: 97.5000
KVP: 120
Thick.: 2.50



10cm

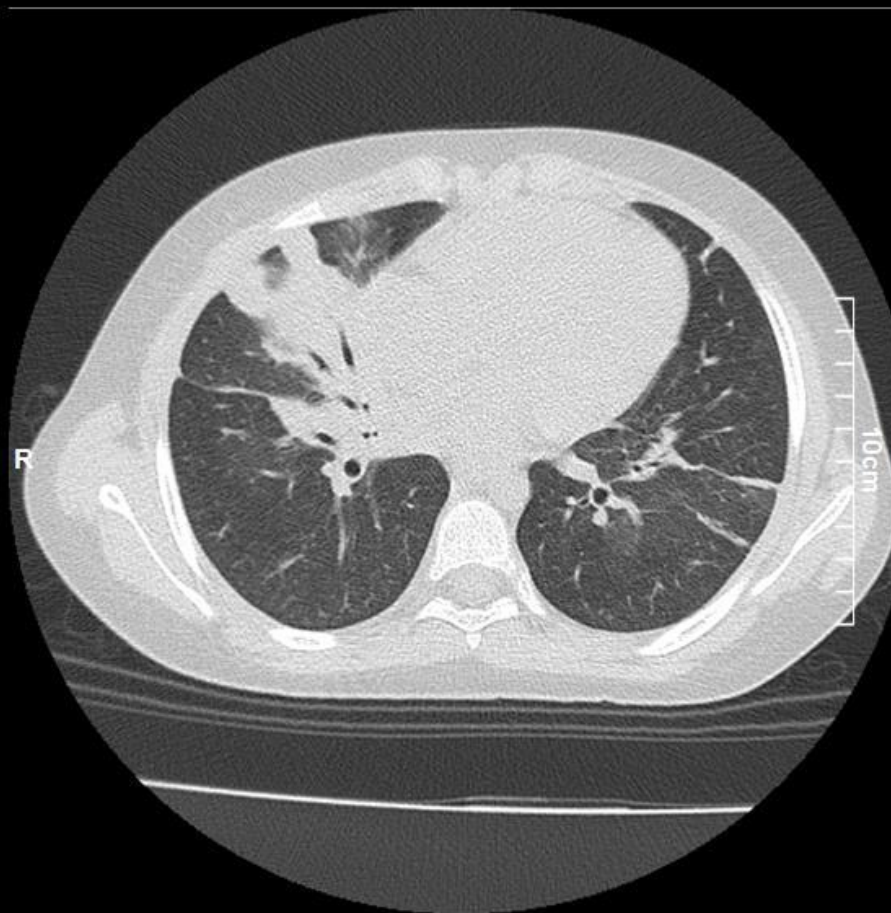
P

Zoom: 108.79%
W/L: 20 / 350

Name: MOSAYEBI^NOORA
ID: 1036863
O / 007Y
CT

A

BAHRAMI HOSPITAL
Operator: N
Ref. Phy:
1403/08/14
12:18.32



im: 166
se: 4
SL: 103.1250
KVP: 120
Thick.: 1.25



10cm

P

Zoom: 108.79%
W/L: -538.6719 / 1669.922







