



# CHALLENGING PEDIATRIC CHEST CASES

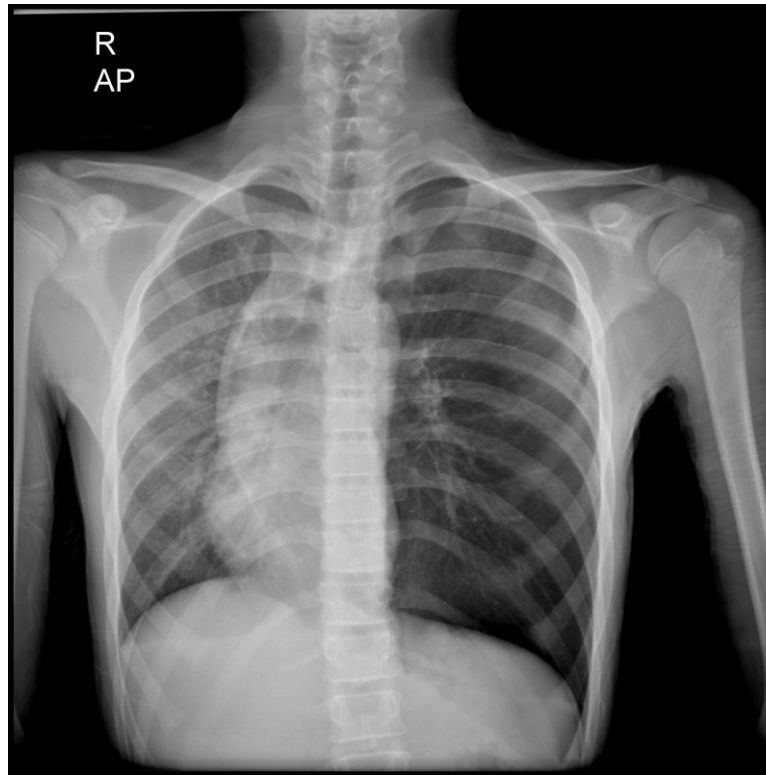
**NEDA PAK**

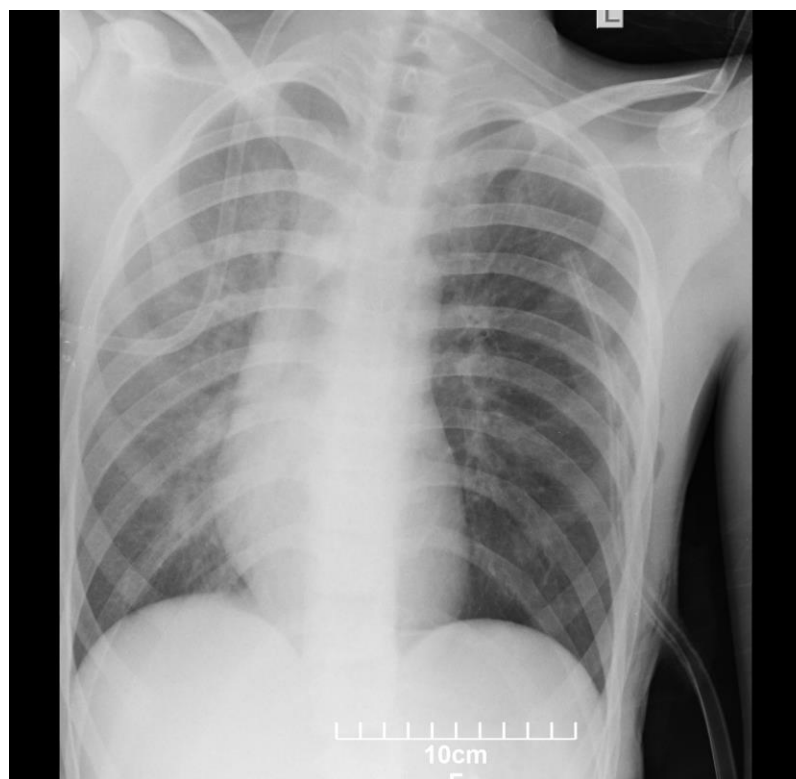
ASSOCIATE PROFESSOR OF RADIOLOGY

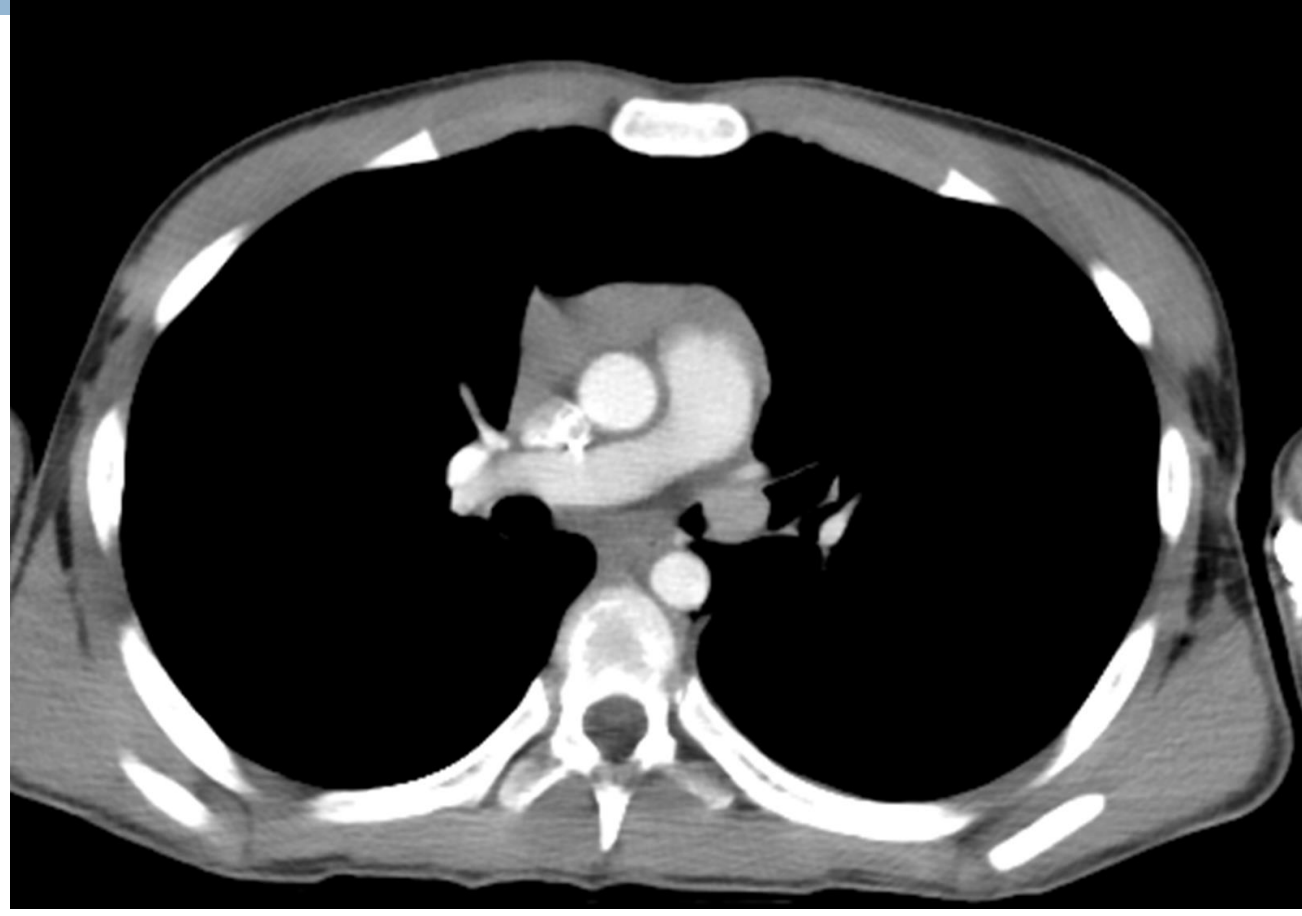
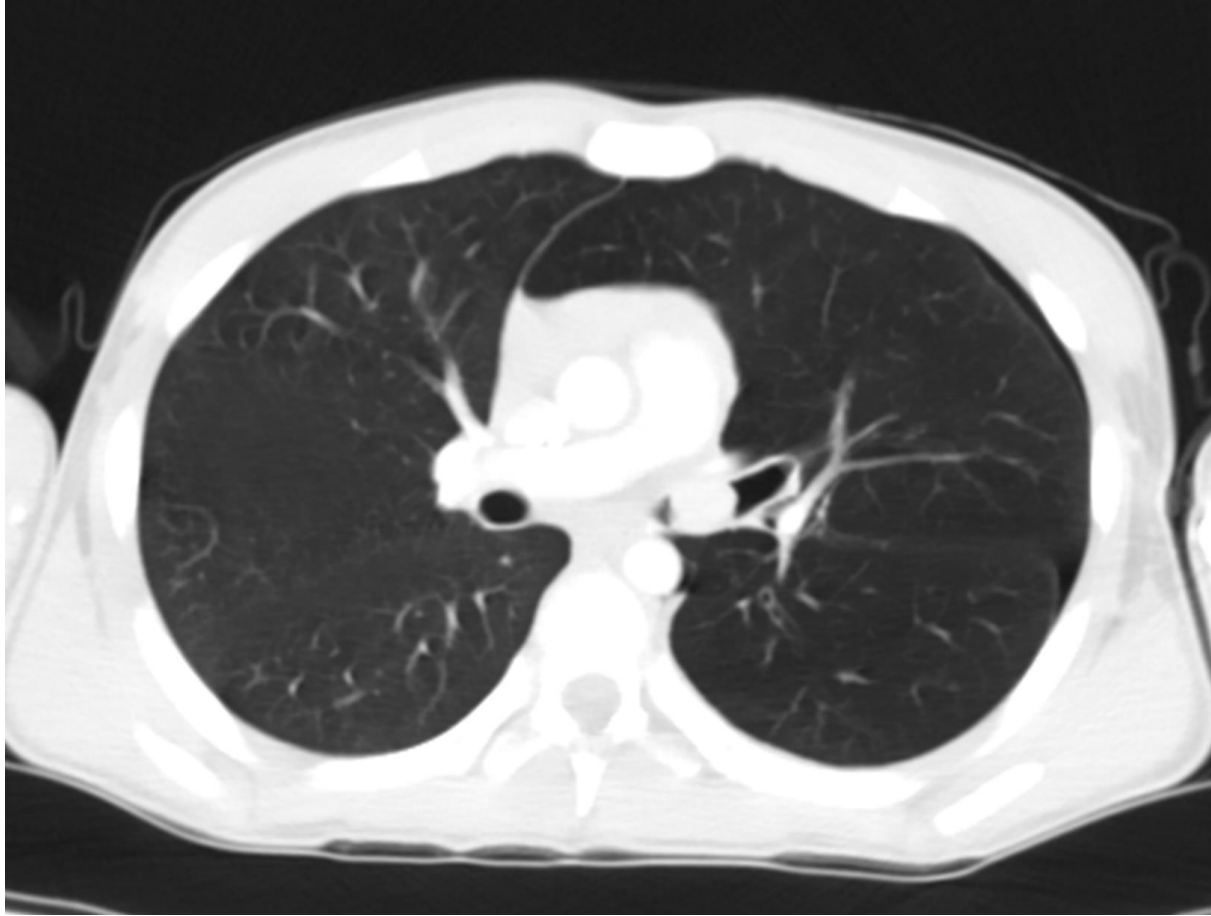CHILDREN MEDICAL CENTER OF EXCELLENCE

TEHRAN UNIVERSITY OF MEDICAL SCIENCES

# 13 YEAR OLD BOY WITH RECENT MULTIPLE TRAUMA DUE TO STREET FIGHT







# PATHOLOGY REPORT

پاتولوژی بافت Left bronchial mass

:Tissue

Left bronchial mass

:Macroscopic

Received specimen in formalin labeled as Left bronchial mass consists of 11 piece of  
tan tissue totally measuring ۰.۸x۰.۵x۰.۳ cm  
SOS:11/1 E:1۰۰%

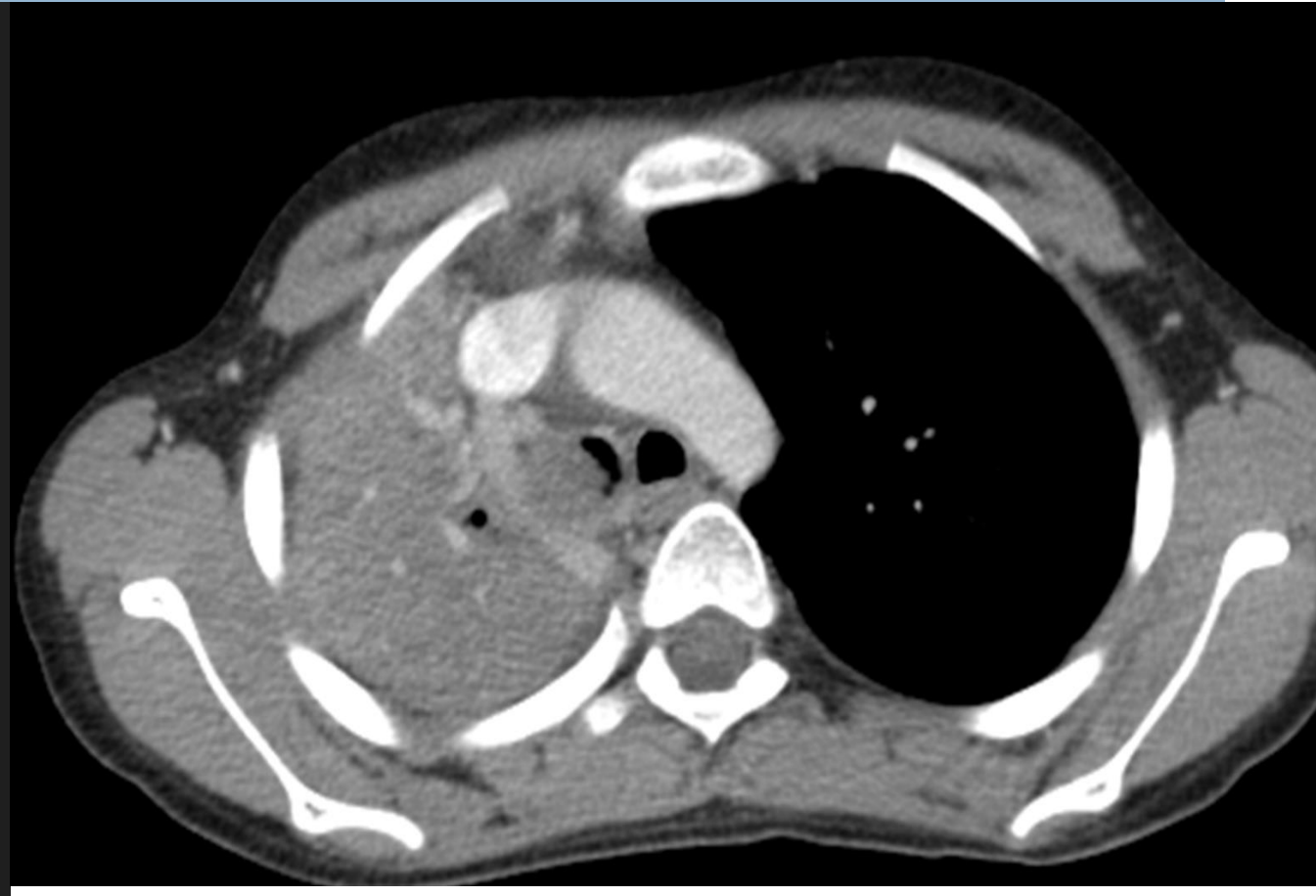
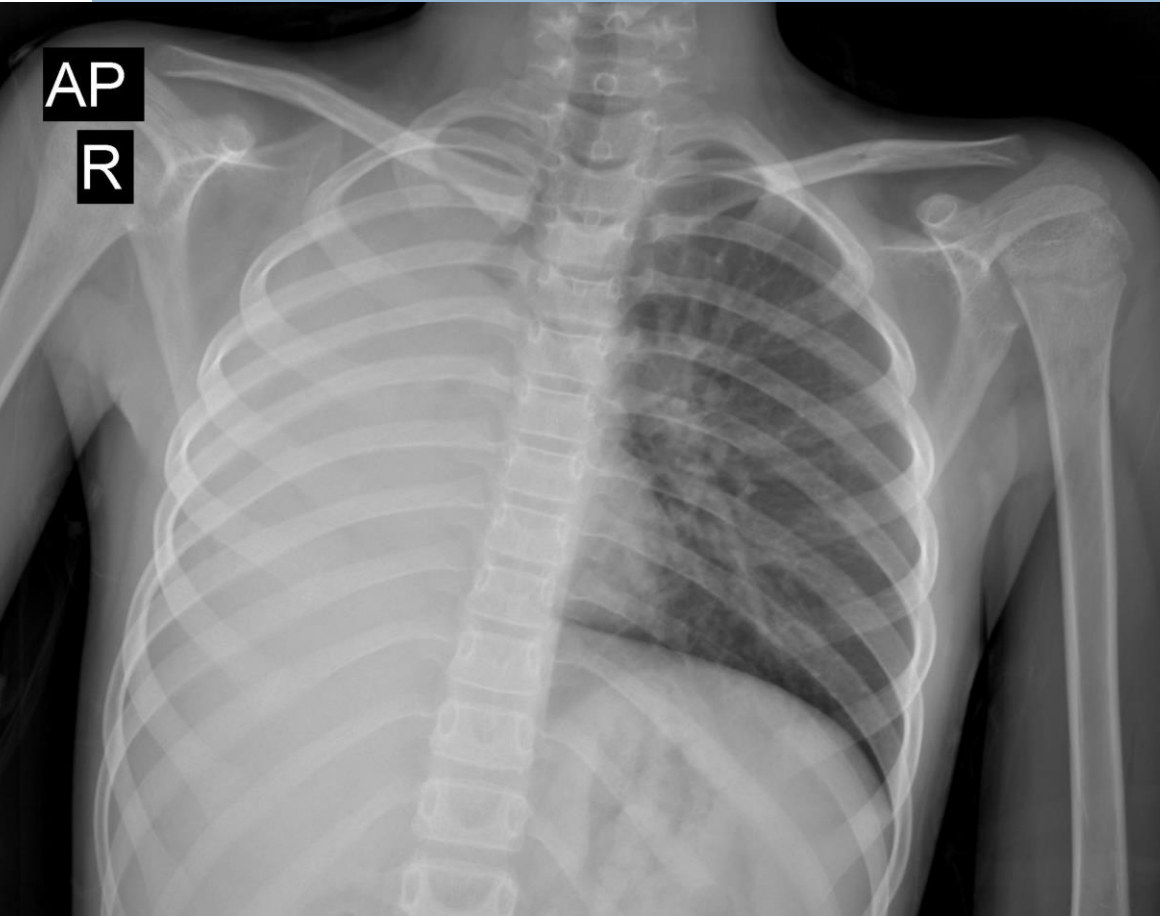
:Microscopic

.Please see the diagnosis

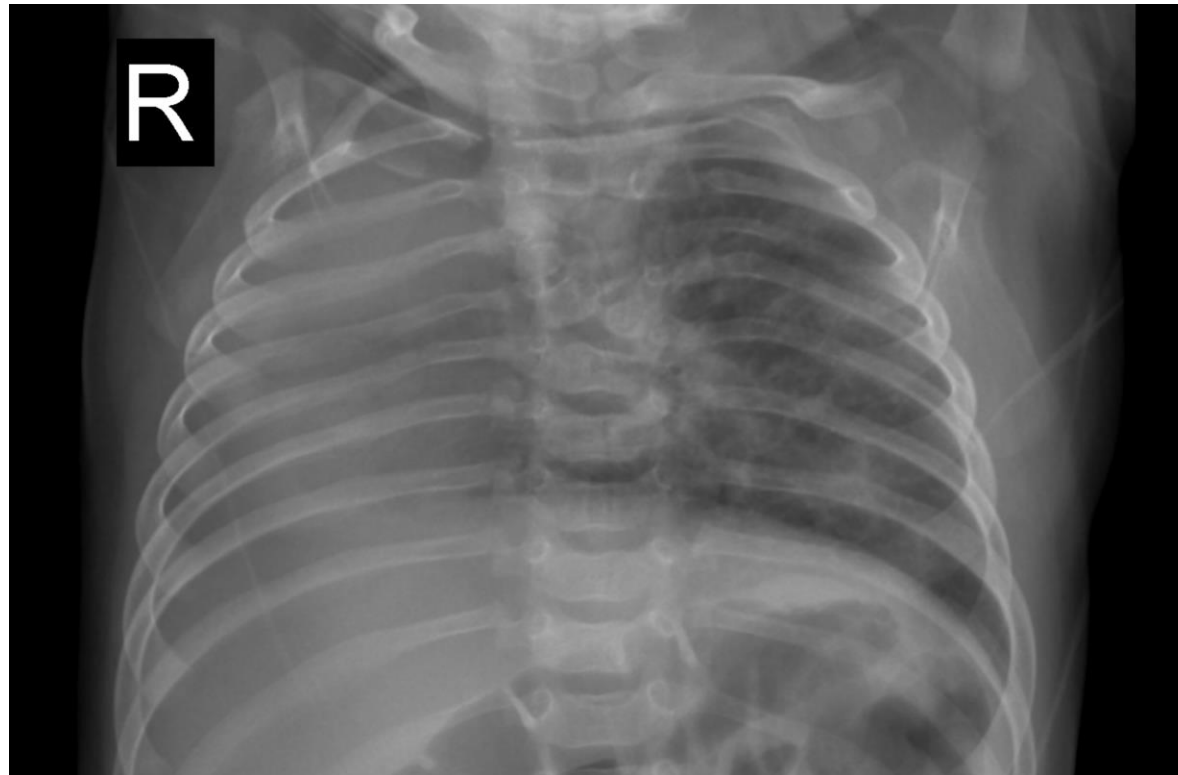
:Diagnosis

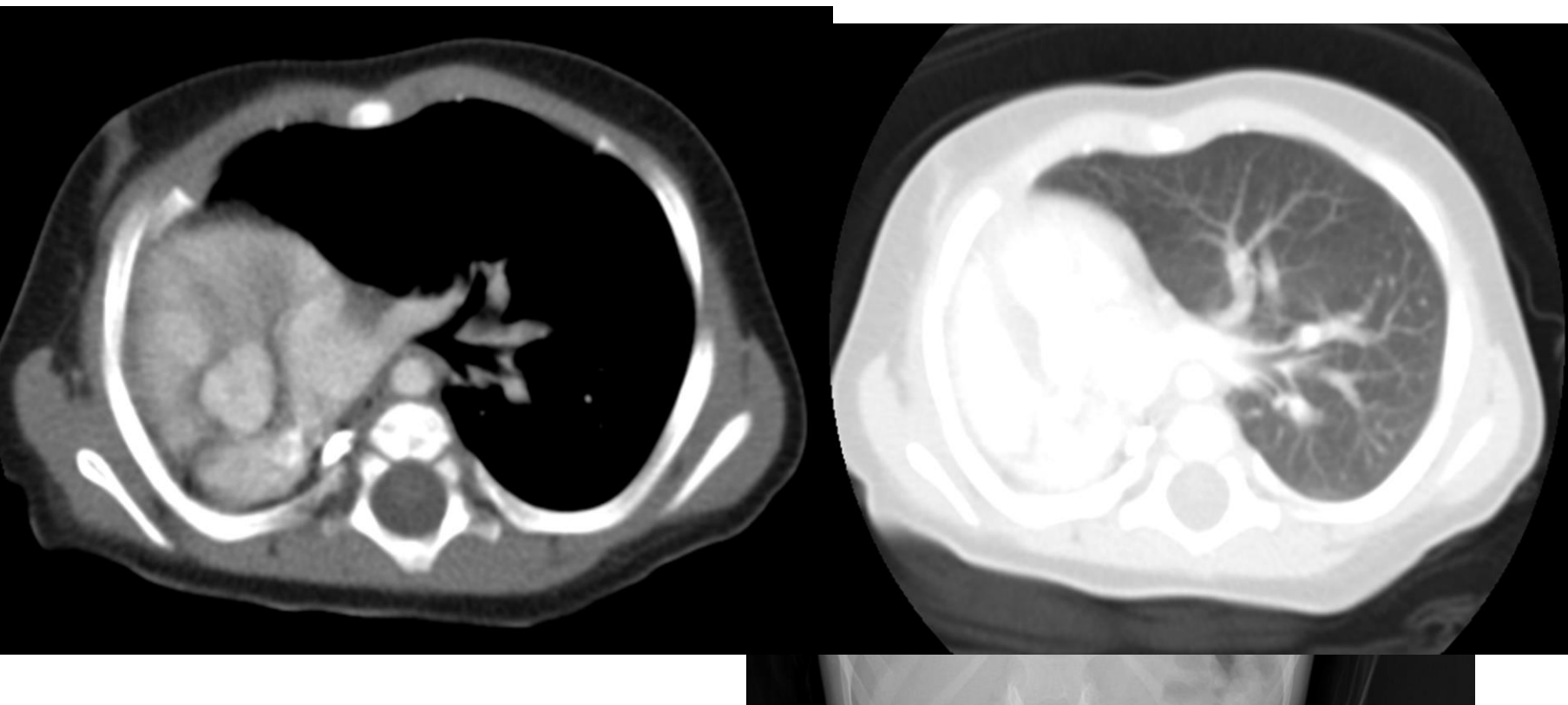
:Left bronchial mass, excision  
Consistent with typical carcinoid/neuroendocrine tuomr, WHO grade 1 -  
ICD-O code M۸۲۴۰/۳

## ENDOBRONCHIAL METASTASIS OF WILMS TUMOR



## 4 MONTH OLD GIRL WITH RESPIRATORY DISTRESS

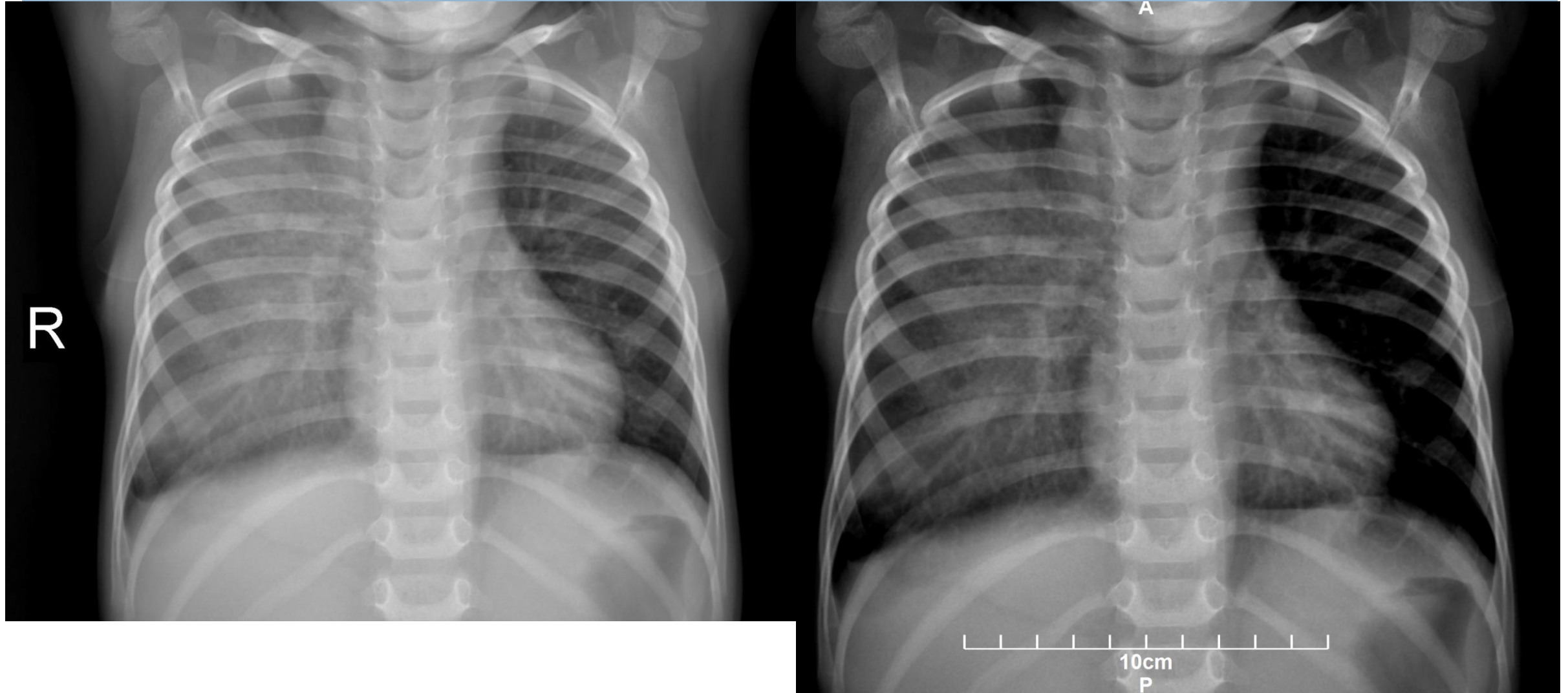




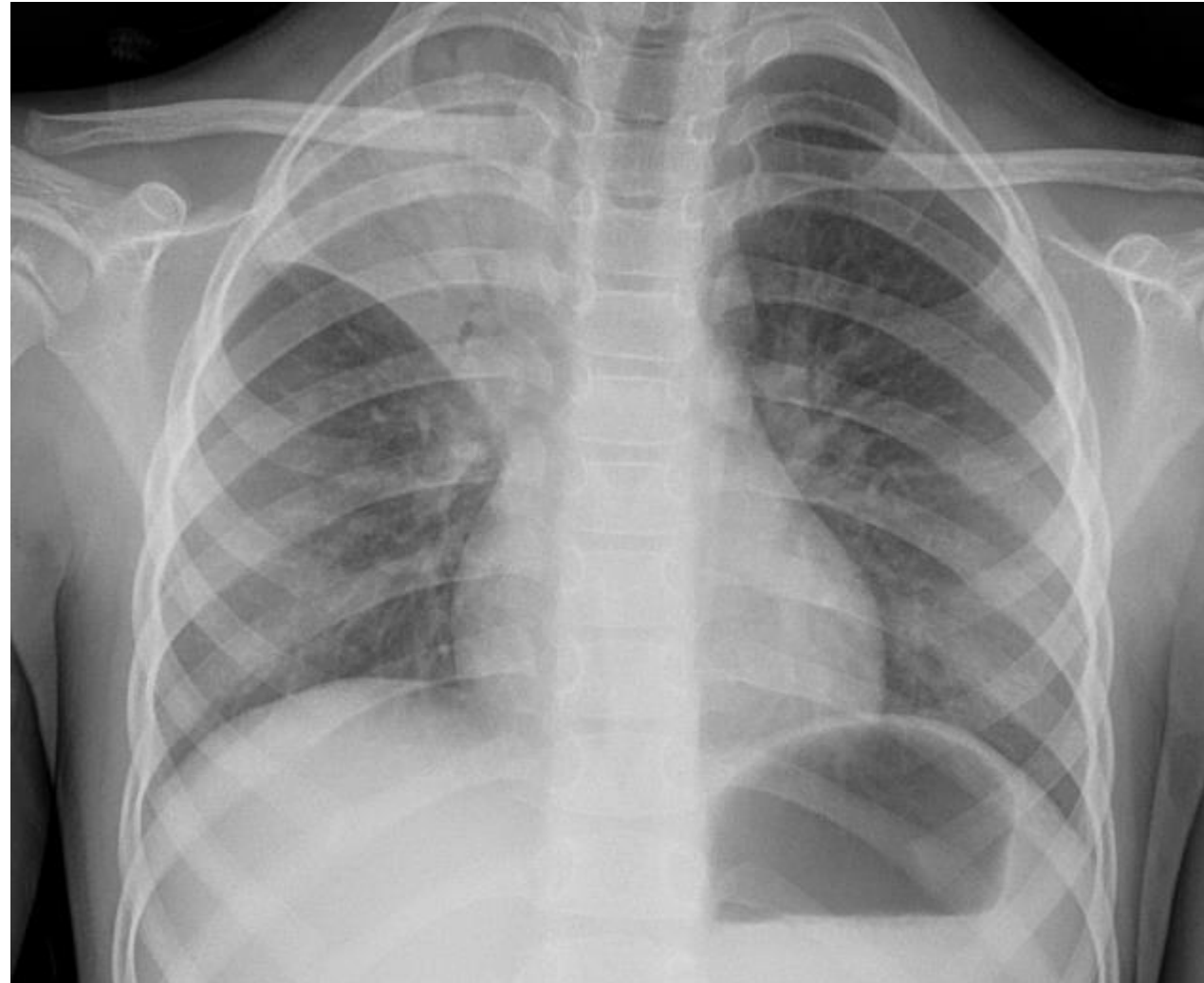
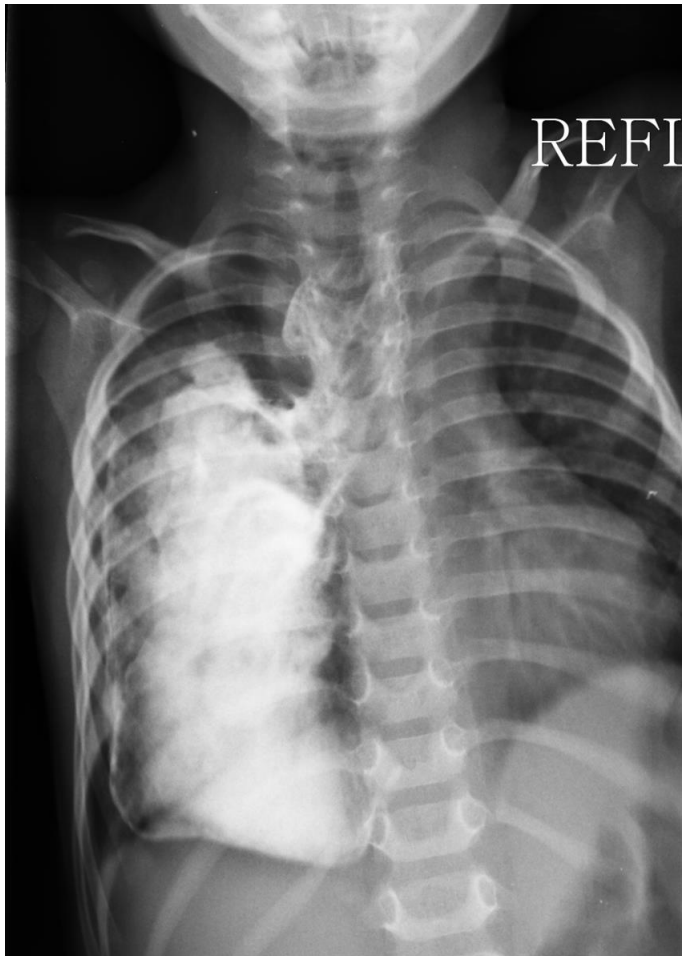Now 7 years  
old



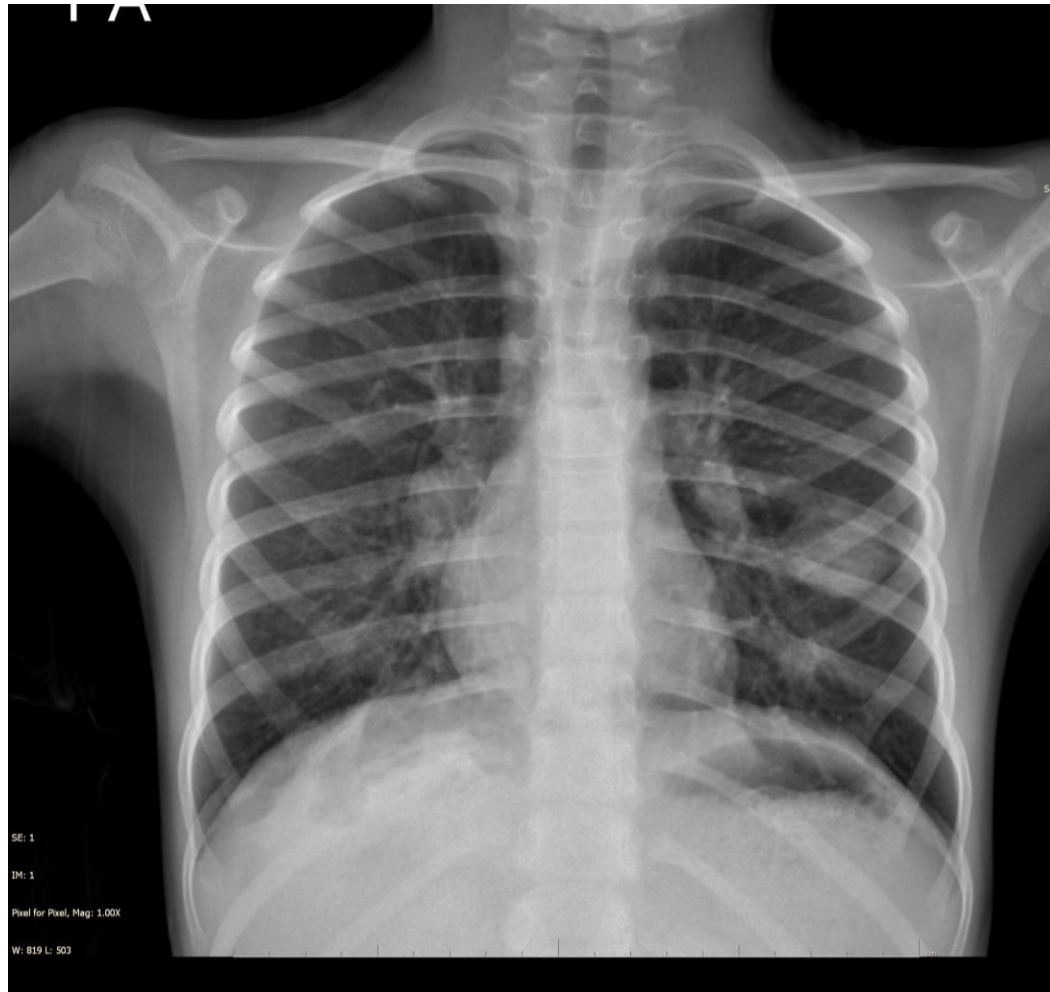
3 YEAR OLD BOY , HISTORY OF LOW GRADE FEVER,  
CORYZA AND MILD TACHYPNEA



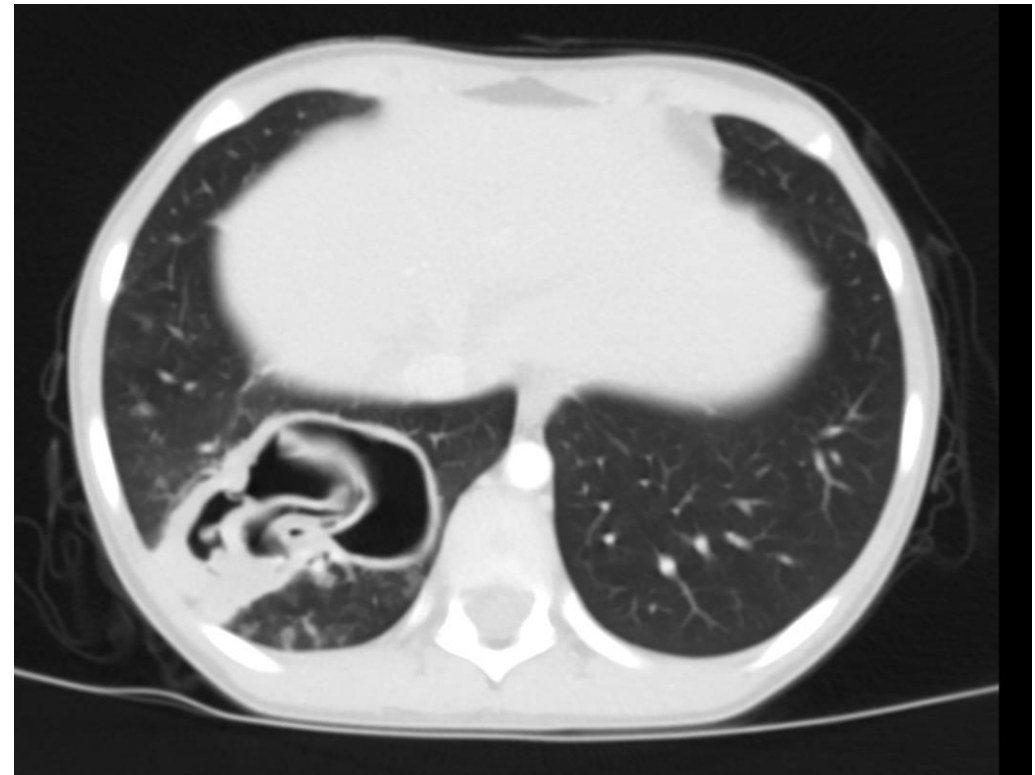
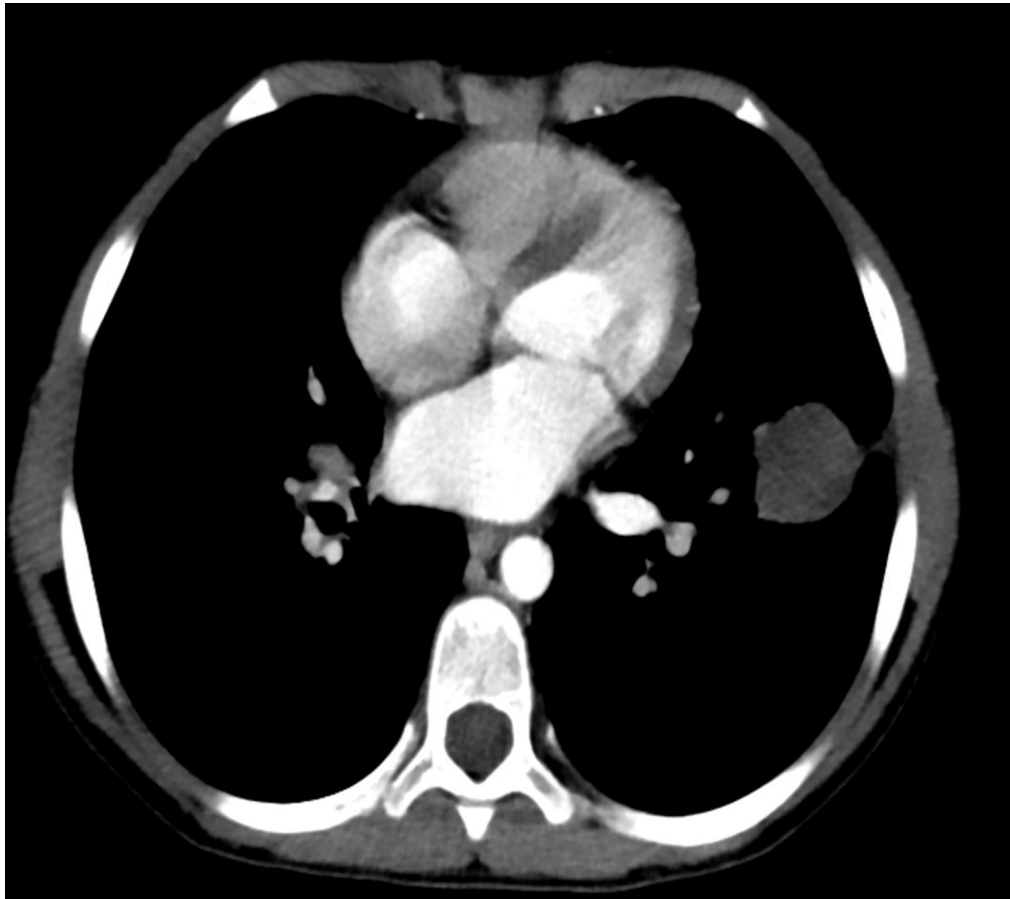
## 3 YEAR OLD BOY , HISTORY OF LOW GRADE FEVER, CORYZA AND MILD TACHYPNEA



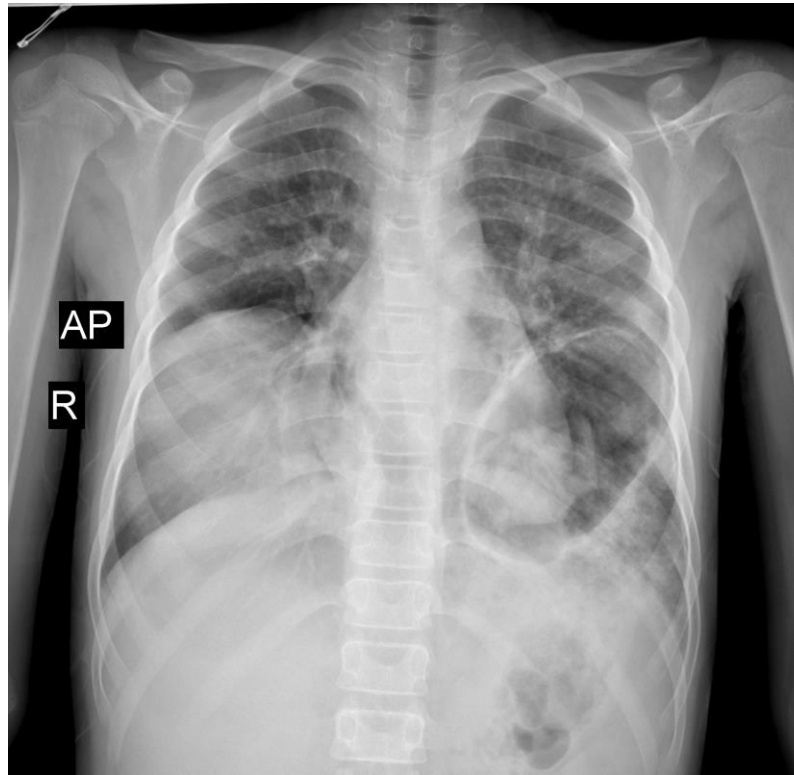
# A 8 YEAR OLD BOY WITH FEVER, PRODUCTIVE COUGH FROM ONE WEEK AGO



## CT SCAN

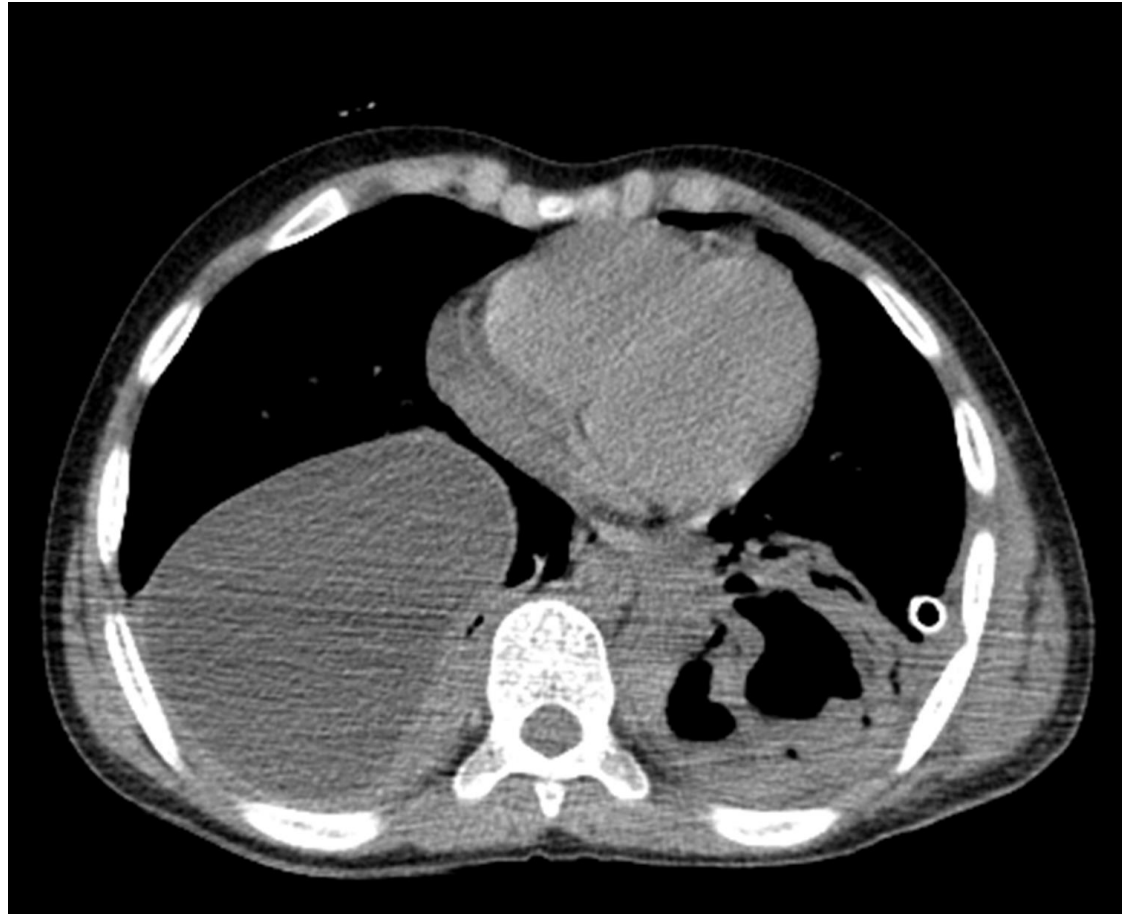


## ANOTHER HYDATIC CYST CASE

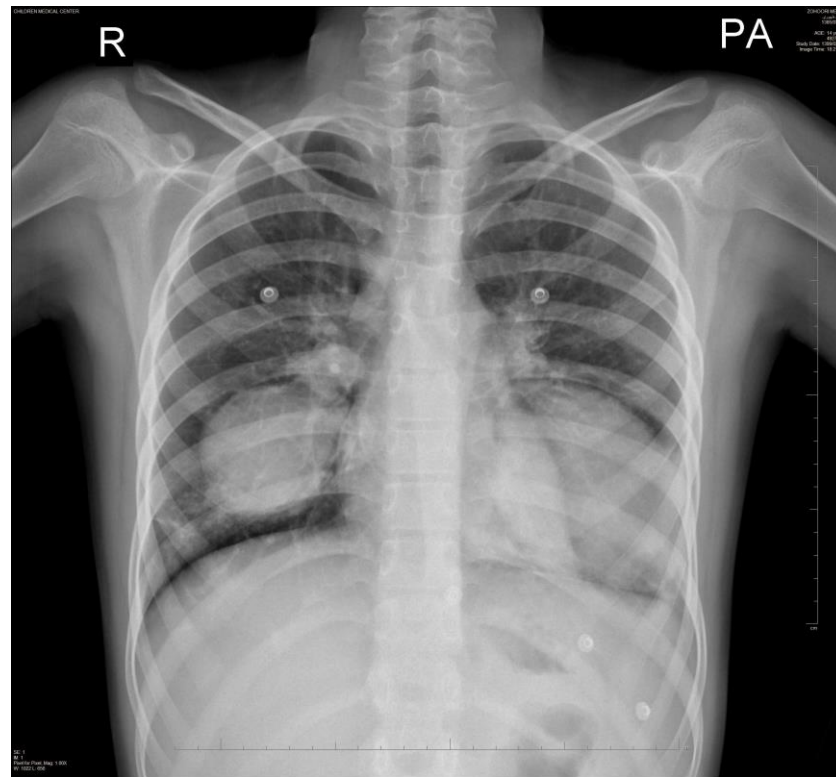




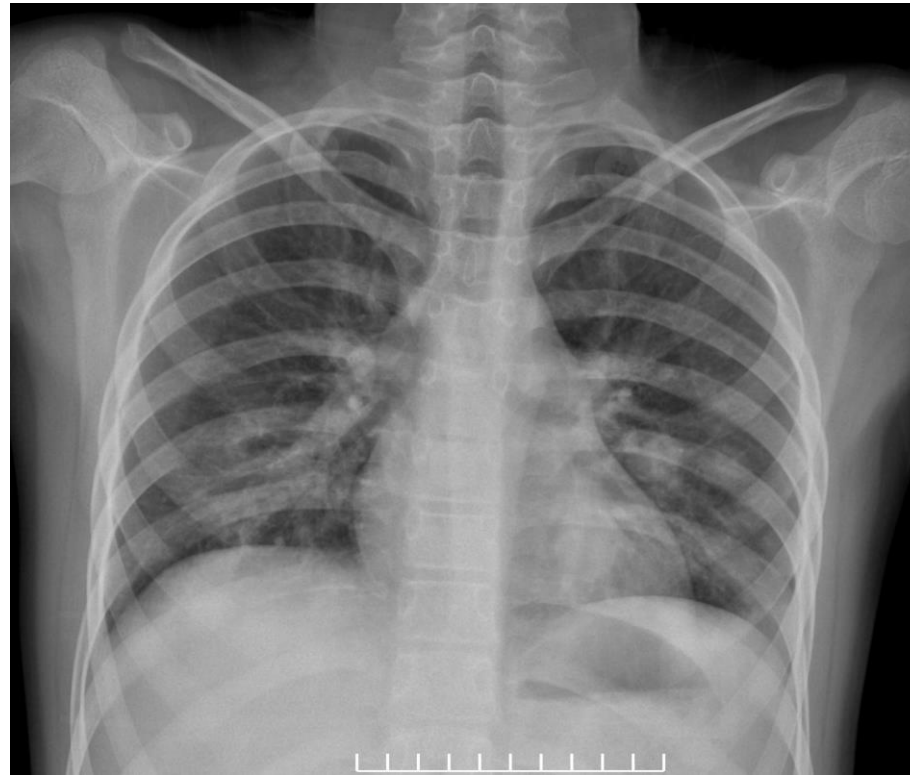
# CT SCAN



# 14 YEAR OLD BOY WITH FEVER, PRODUCTIVE COUGH RECENTLY AND HX AND LONG TERM COUGH AND PNEUMONIA

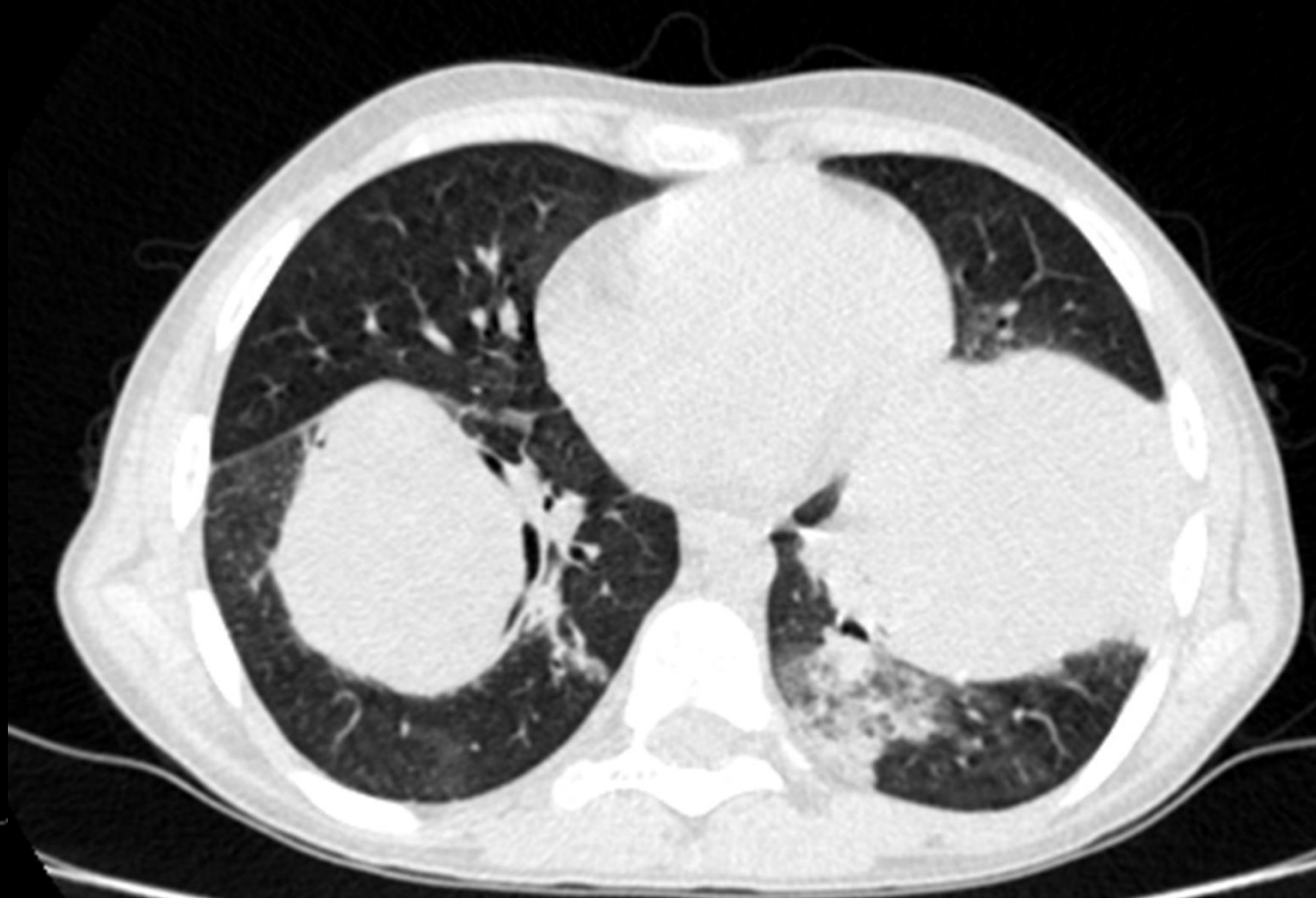
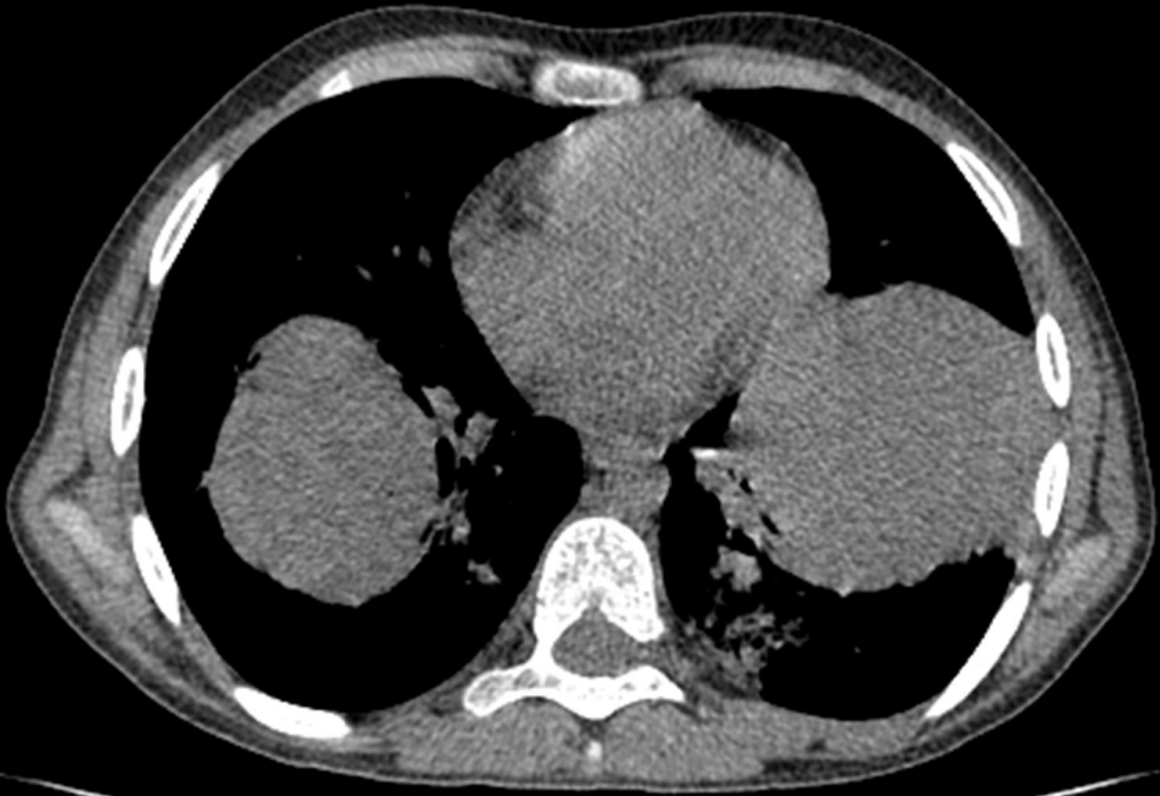


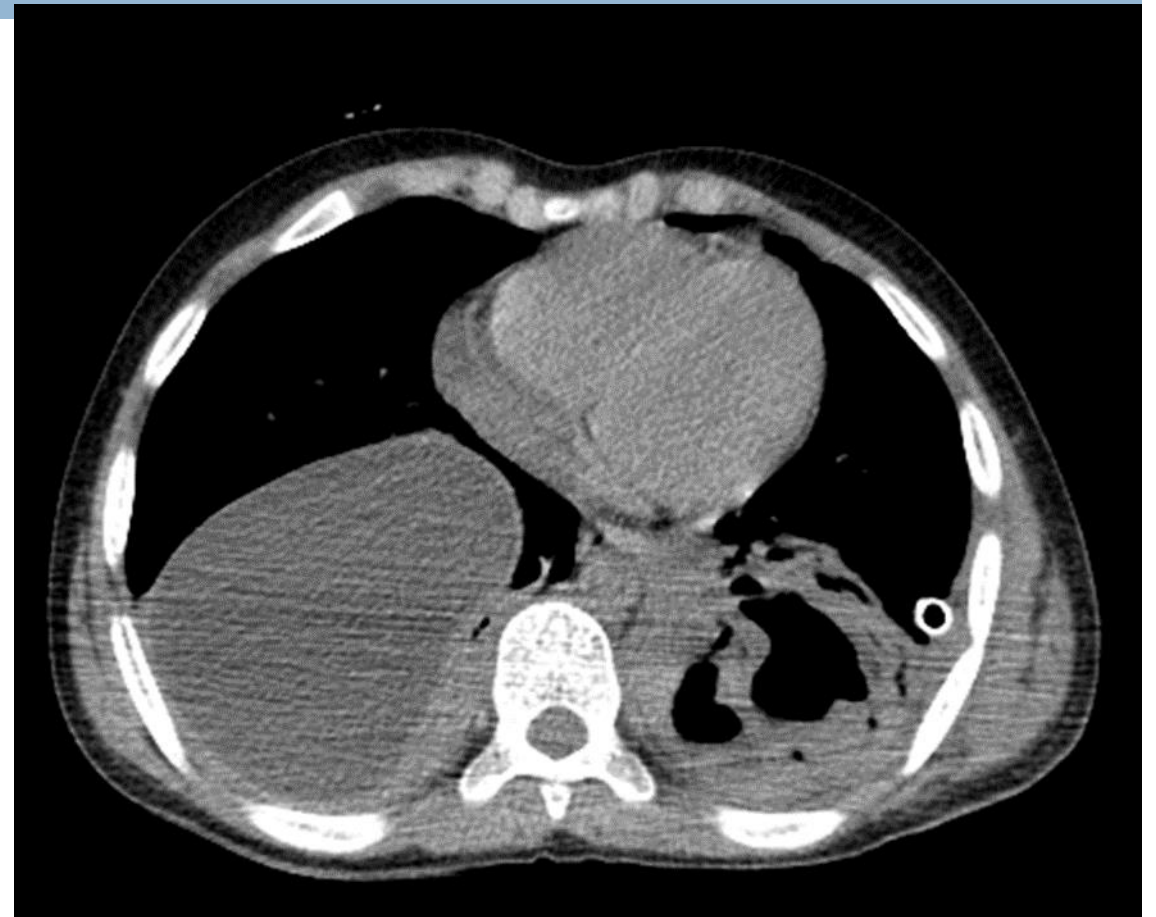
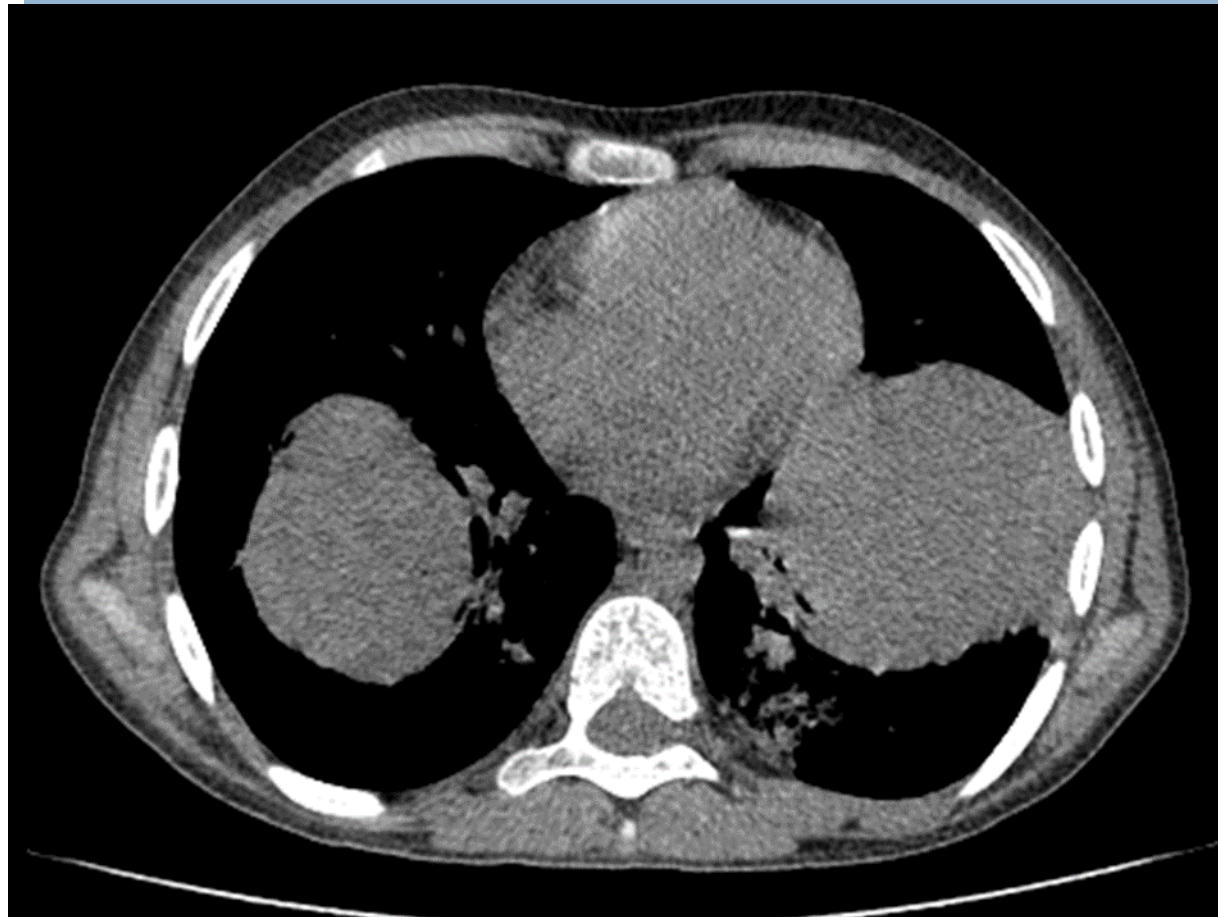
## CXR 4 MONTHS EARLIER

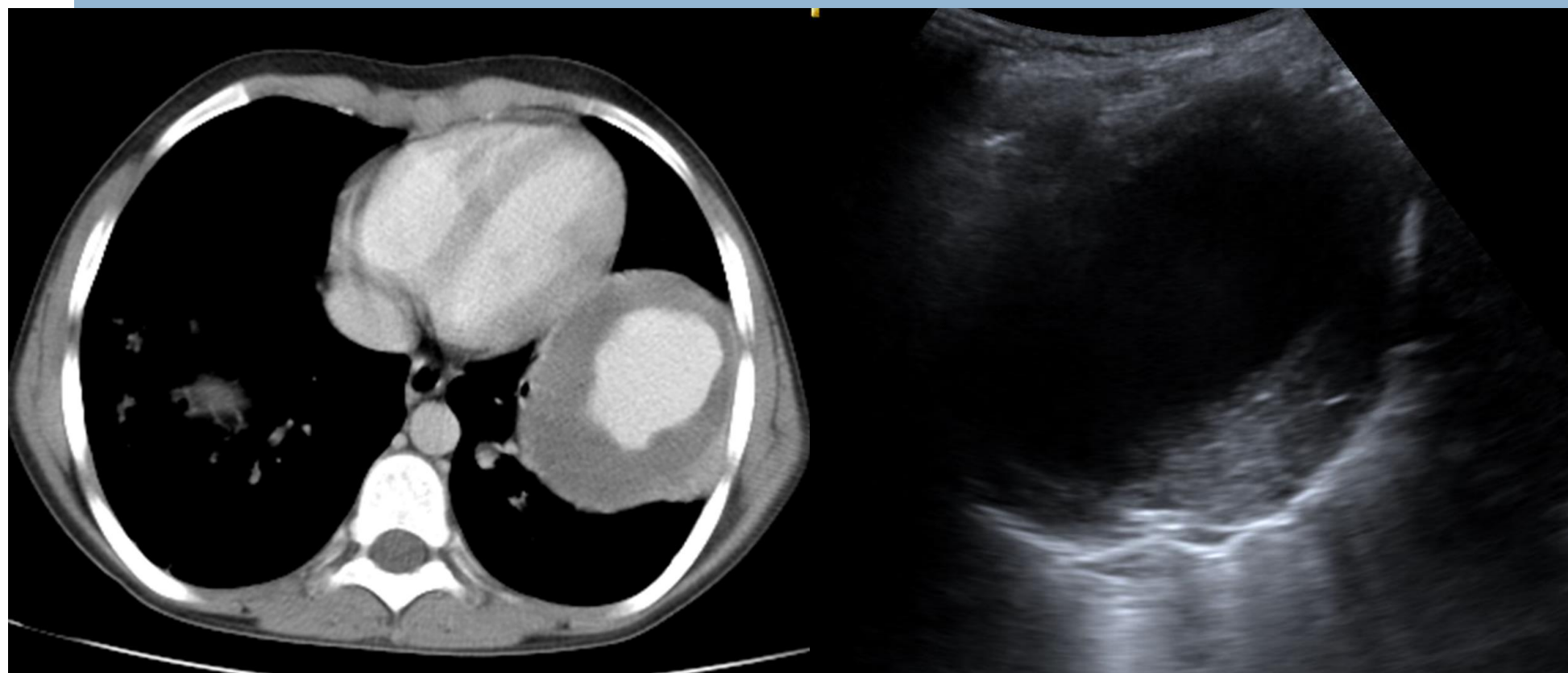




## NON CONTRAST CT SCAN

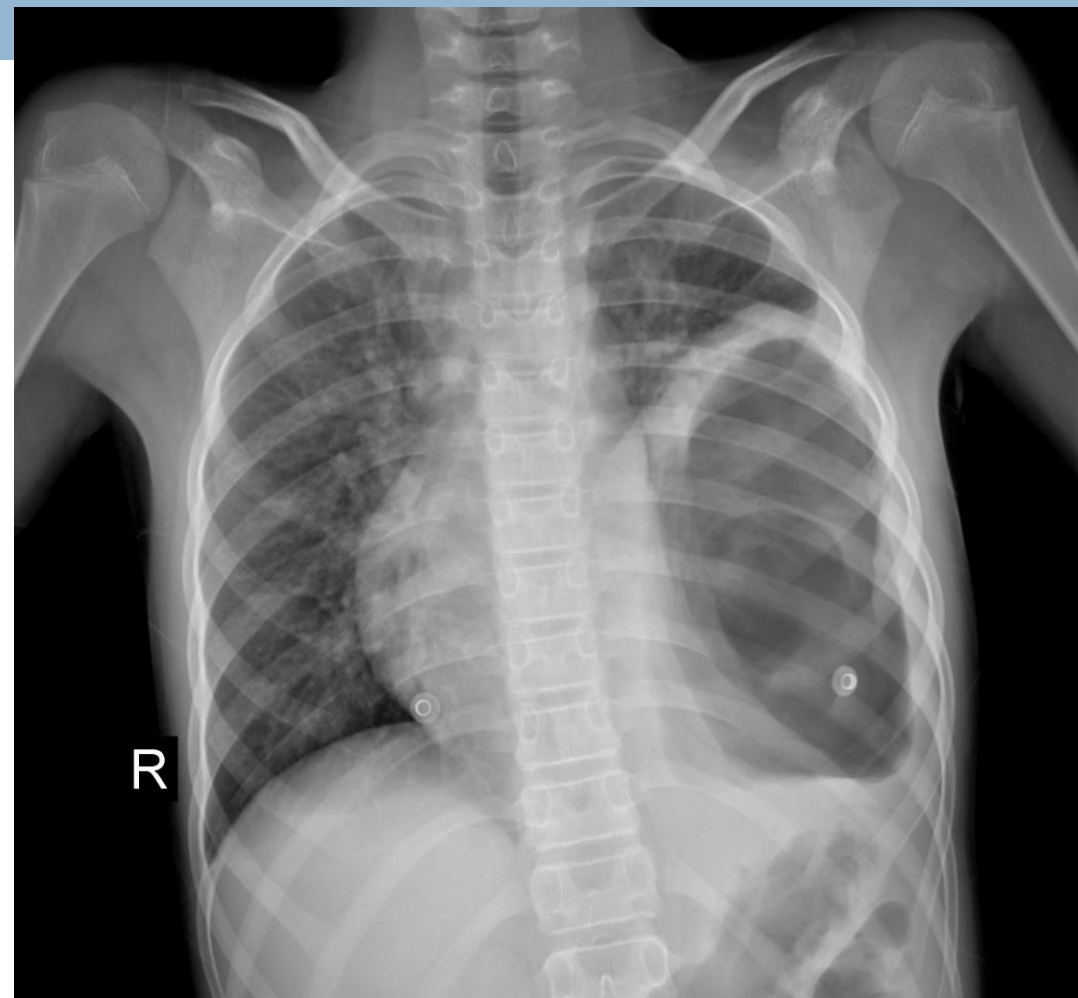
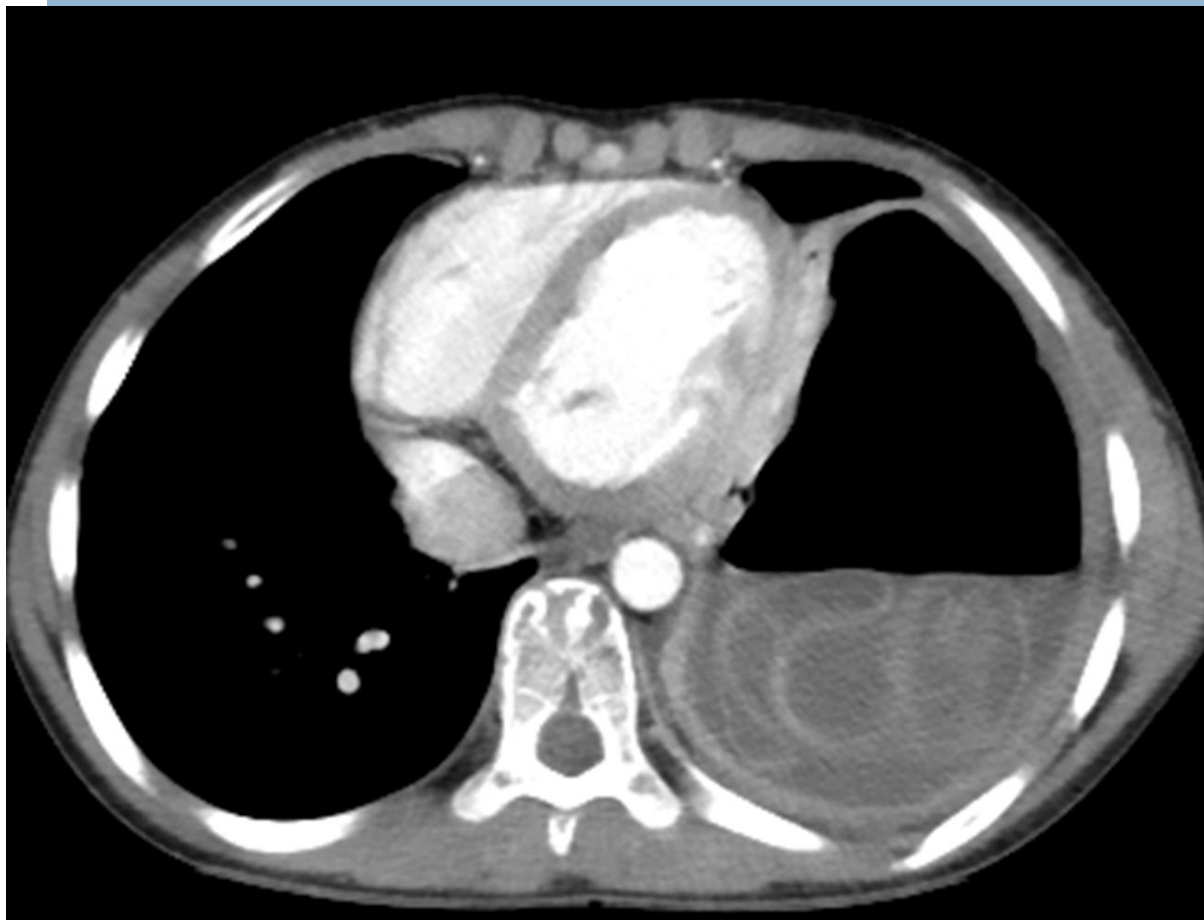






**Pulmonary aneurysm**





**THANKS FOR YOUR ATTENTION**

